Federal Bureau of Prisons
Clinical Practice Guidelines

Management of Acute Upper Extremity Conditions

DECEMBER 2012

INDEX

Collateral Ligament Injury to the Thumb

Distal Radius Fractures

Closed Fist/Fight Bite

Tendon Injuries of the Finger

Metacarpal Fractures

Proximal Interphalangeal Joint (PIPJ) Dislocations

Scaphoid Fractures

Chronic Shoulder Pain

Each provider brings a different level of clinical experience in dealing with musculoskeletal problems. It is the responsibility of the provider, relying on their experience and knowledge of the condition, to determine the best time to treat in-house or refer for consultation. The following guidelines help with that decision making by supplementing what the provider may already know. Use of additional resources—including the physician(s) providing orthopedic services for the institution—is encouraged.

The electronic version of this PDF document contain allows the reader to double-click on "blue boxes" in the algorithms, which link to relevant pictures or more in-depth information in the text. The blue boxes resemble this:

DECEMBER 2012

Management of Collateral Ligament Injury to the Thumb

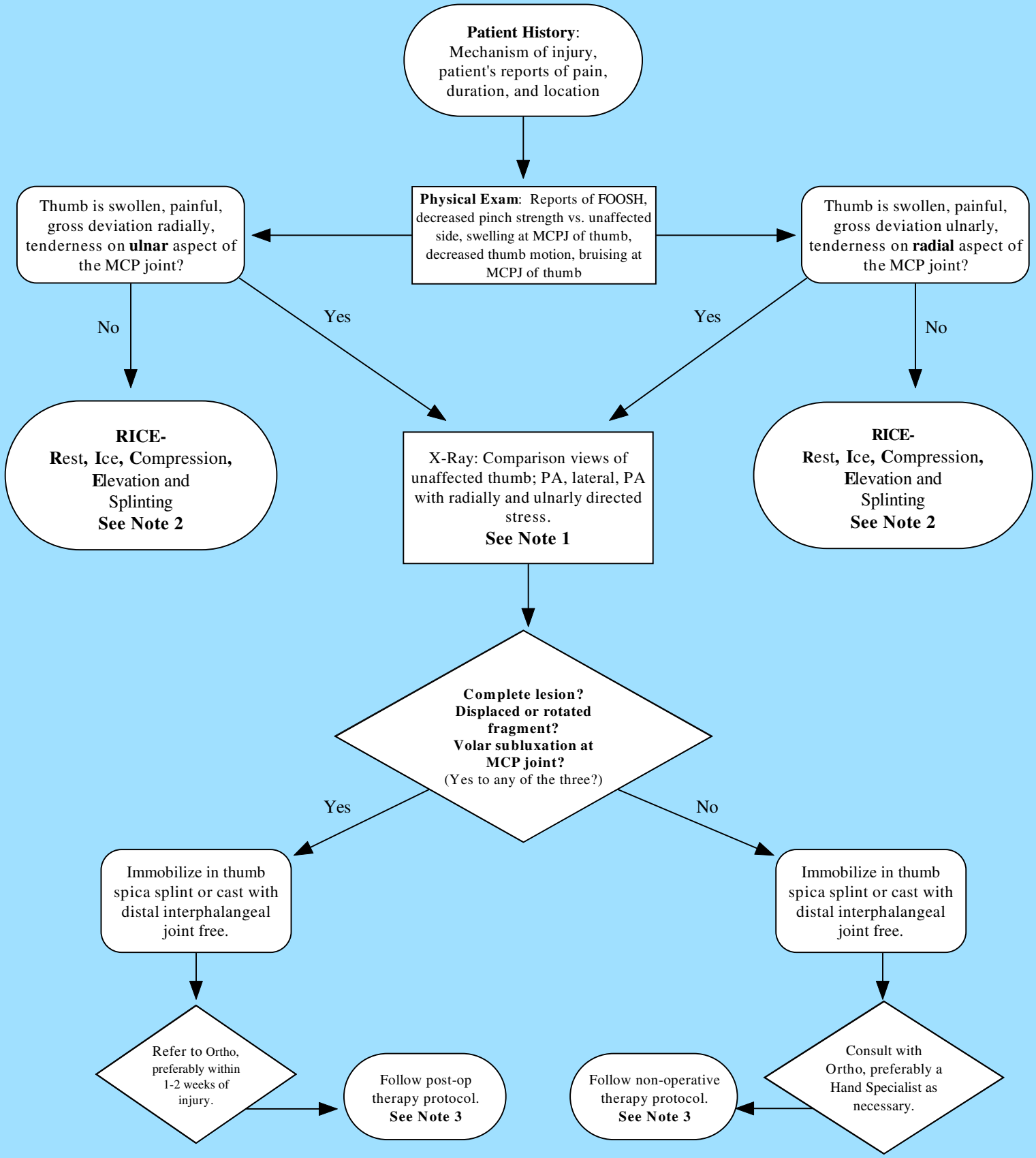

Note 1- Assess joint stability by stressing the joint in full extension and in 30 degrees of flexion, both for the injured and uninjured thumb. The stress is applied in the direction opposite to the injured ligament; for example, an ulnar collateral ligament tear would have stress applied in a radial direction. Compare the test with the uninjured side. More than 15 degrees difference from the uninjured thumb or laxity greater than 35 degrees and a soft end point indicate a rupture of the ligament.

Note 2- For UCL injuries, the **s**plint should position thumb MPJ in slight flexion with IPJ free to move. CMC joint should be slightly opposed, i.e., position thumb directly under the index finger while still maintaining the first web space. For RCL injuries, the splint should position the thumb MPJ in full extension with the IPJ free to move.

Note 3- In-depth protocols can be found in ***"BOP Clinical Practice Guidelines for Management of Collateral Ligament Injury to the Thumb."***

Federal Bureau of Prisons
Clinical Practice Guidelines

MANAGEMENT OF COLLATERAL LIGAMENT INJURY TO THE THUMB

December 2012

PURPOSE

The Federal Bureau of Prisons Clinical Practice Guidelines for Management of Collateral Ligament Injury to the Thumb provide evidenced-based recommendations or guidelines for the outpatient management of federal inmates with acute collateral injury to the thumb.

This evidence-based protocol is designed as a guide so that the front-line clinician can manage acute hand injuries with the confidence inherent in standardized practice. A thorough examination and close, consistent follow-up care are essential for achieving satisfactory outcomes.

REFERENCES

Brown, A. (1998). Ulnar collateral ligament injury of the thumb. In: Clark GL, Shaw Wilgis EF, Aiello B, Eckhaus D, Eddington LV, eds. *Hand Rehabilitation: A Practical Guide*. 2nd ed. Philadelphia: Churchill Livingstone; 1998: 369-375.

Campbell PJ, Wilson RL. Management of joint fractures and intraarticular fractures. In: Mackin EJ, Callahan AD, Skirven TM, Schneider LH, Osterman AL, Hunter JM, Robert RR, eds. Rehabilitation of the Hand: Surgery and Therapy. Vol 1. 5th ed. St. Louis, MI: Mosby; 2002: 406-408.

Perron A, Brady W, Keats T, & Hersh R. (2001). Orthopedic pitfalls in the emergency department: Closed tendon injuries. *Am J of Emer Med*, 19 (1), 76-80.

DEFINITIONS

- ***Ulnar collateral ligament (UCL) injury at the thumb****:*
  Also known as “Skier’s Thumb” or “Gamekeepers Thumb”; describes a stretch or tear to the ligament or ligaments that support the metacarpalphalangeal joint (MCPJ) on the ulnar side of the thumb. Ulnar collateral ligament injuries have been noted to be 10 times more common than radial collateral ligament injuries (see below). The mechanism is an abrupt, forced radial deviation of the thumb. This condition may result from a *fall onto an outstretched hand* (FOOSH) with an abducted thumb. Differentiating complete tears from

partial tears may be difficult. The physical findings include tenderness, ecchymosis (i.e., bruising) and swelling along the ulnar border of the joint.

The patient will often manifest a weakened ability to grasp objects or perform such tasks as tying shoes and tearing a piece of paper. Other complaints include intense pain upon catching the thumb on an object, such as when reaching into a pants pocket.

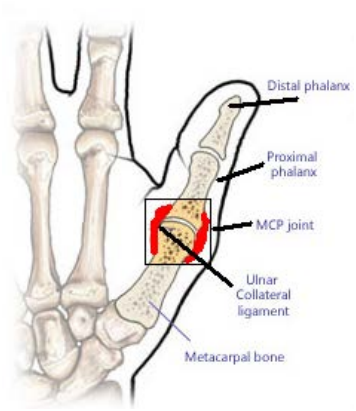

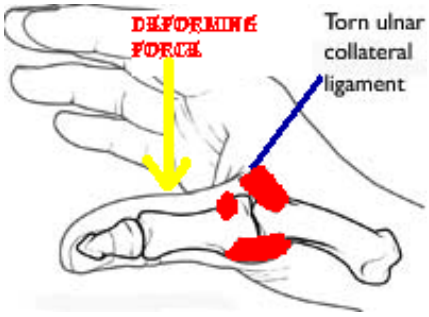

- ***Radial collateral ligament (RCL) injury at the thumb:***
  Radial collateral ligament injuries are significantly less common than UCL injuries, but may be equally as debilitating. Some studies have shown that UCL injuries occur 10 times more frequently than injuries to the RCL. The mechanism of RCL injury is forced thumb adduction or torsion on a flexed MCP joint.

PROCEDURES

1. Introduction:

Acute ligamentous injuries involving the thumb MCP joint typically present with pain, depending on the severity of the injury (Grade I, II, or III tear) and whether other structures have been injured. Swelling, instability, and deformity can also be observed at the affected joint. Swelling increases with both the severity of the injury and the number of associated structures disrupted; it generally decreases with the passage of time.

- **Grade I ligament tears** result in mild to moderate pain at the site of the injury. A stress test, i.e., lateral stress to the ligament, results in a firm endpoint because only a small percentage of the fibers are actually torn. Ligament stress testing the joint and direct palpation elicits focal tenderness, but no loss of stability.

- **Grade II ligament tears** involve disruption of a greater proportion of ligamentous tissue. Swelling and pain are typically more pronounced than for Grade I injuries. Stress testing reveals a softer, but still noticeable, endpoint. The joint may partially "open up" and be partially unstable when stressed, but the joint is actively stable through full range of motion. Point-specific pain is also noted.

- **Grade III ligament tears** are complete disruptions of the ligament. In the acute phase, there is marked swelling and pain. During stress testing, the ligament yields completely to force and there is no endpoint. The joint itself is usually reduced at rest, i.e., stable at rest, but there is considerable subluxation seen with stress testing and with active range of motion. An avulsion fracture at the affected joint is often observed with this injury, representing bony disruption of the insertion of the ligament.

Although injuries to both the radial and ulnar collateral ligaments can occur simultaneously, usually one of the ligaments is more involved, i.e., more tender than the other. Swelling and pain are greater when both ligaments are injured.

2. Evaluation:

Inspection of the thumb for deformity, laceration, or other signs of injury, including nail bed injury, is imperative. Other soft tissue injury may coexist, and management priorities are determined by the severity of each. Deep skin lacerations may expose fractured bone or torn tendon and should be addressed first. Nail bed injuries and simple lacerations are noted, and treatment is provided after completion of the examination.

- Ask the patient to perform all thumb movements without resistance (as shown below), noting any abnormalities or deficiencies of motion.

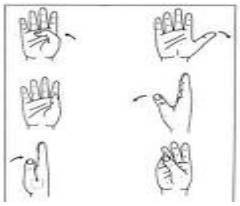



- Palpate the distal and proximal phalanges, first (thumb) metacarpal, interphalangeal (IP) joint, metacarpophalangeal joint (MCPJ), and carpometacarpal (CMC) joint for tenderness and deformity. Check for pain and swelling directly over the ligament at the base of the thumb.

- Patients will often have a difficult time grasping objects or holding objects firmly in their grip. Have the patient repeat these movements against active resistance, looking for weakness and instability by comparing the affected and unaffected sides.

- The ulnar collateral ligament is properly tested with the thumb MCPJ in 30 degrees of flexion, as this isolates the UCL. Accessory UCL and volar plate are tested in extension. With the MPJ in extension, increased laxity of between 15-30 degrees can indicate disruption of the UCL and/or other ligamentous structures. With the MPJ in 30 degrees of flexion, laxity greater than 30 degrees can confirm the initial finding when the MCPJ was in extension. A soft-end point indicates complete tear. (*See the illustration below.)*

Stress test for ulnar collateral ligament tear:

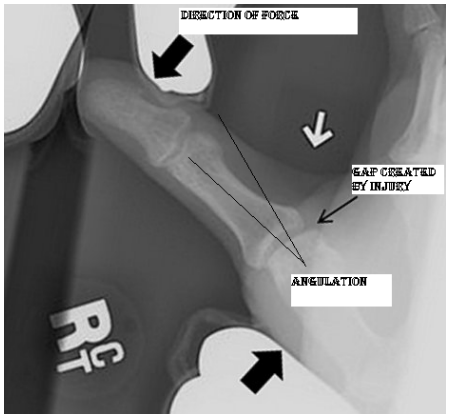

An end point is felt when the thumb is first flexed, then radially deviated, and the angle between the first metacarpal and the proximal phalanx is assessed.

Stress x-ray shows apparent radial collateral ligament disruption:

3. Classification and Treatment:

Principles of ligament management include:

- Prevent lateral stress to the affected joint.
- Control the pain.
- Control edema.
- ***Never*** sacrifice stability for mobility.
- Complications include pain, swelling, and stiffness of the joint that may persist for ***months***.

Initially, all sprains of the thumb should be treated with the **RICE** principle (**R**est, **I**ce, **C**ompression, and **E**levation). An x-ray (PA, lateral, and oblique views) should be taken to rule out any fractures.

- ***Grade I and Grade II tears:*** Partial tear or attenuation resulting in pain, swelling, and stiffness —— but no significant instability. These injuries are treated in a thumb spica cast for 4 weeks, with the IP joint left free. At 4 weeks, the cast is removed and, if the patient is pain-free, replaced with a removable splint (*see pictures below*). The MCP joint is then mobilized with active and active-assisted range of motion (ROM) over the course of 3 to 4 weeks. Avoid radial-directed stress such as opening jars or doors for 10 to 12 weeks. If pain is controlled, strengthening for pinch can be initiated at week 10. **Obtaining end range motion IS NOT as important as obtaining a stable, pain-free joint.**

  If the patient is not pain-free on re-exam at 4 weeks, a cast (preferred) or splint should be re-applied for another 2 weeks, unless otherwise stated by MD.

- ***Grade III tears:*** Complete tears that render the joint unstable must be stabilized through surgical repair. A **Stener Lesion** can occur with UCL injuries when the distal portion of the ligament becomes lodged between the adductor pollicis aponeurosis and its normal position. Such injuries are grossly unstable and usually will not heal with a stable joint, therefore requiring surgical intervention. A thumb spica cast or splint should be applied for acute injuries even if the patient is awaiting consultation for surgery. This is done for protection and comfort.

  (See illustration and x-ray on the next page.)

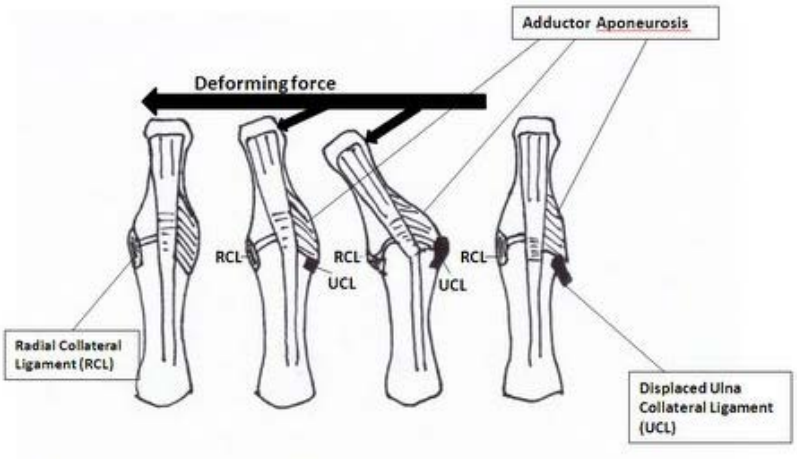

4. **Splinting Options**:

A cast must be forearm-based to properly distribute pressures, while splints can be either forearm or hand-based, depending on the patient and other injuries.

5. **Possible Complications**:

- Chronic instability and weakness of pinch.
- Persistent pain and arthritis.
- Decreased ROM of MCP and IP joint.
- Wide grasps like opening jars or lifting wider cups should be avoided for 10 to 12 weeks, as these activities put direct strain on the ulnar collateral ligament and can stress the injury.

Warning/Caution

Even with successful healing, the thumb may remain tender to palpation for 3–6 months. In addition, the inmate may note pain with when using a forceful grip (and other activities that stress the ligament) for 6 months or longer. Much like PIP joint injuries of the finger, the thumb MCPJ will likely remain larger than it was before the injury, due to scar tissue formation. The inmate should be educated about this likelihood early on in the treatment.

6. **Clinical Pathway**:

See attached *Management of Collateral Ligament Injury to the Thumb* algorithm.

Treatment Guidelines for Ulnar and Radial Collateral Ligament Injuries		
Week	**Non-Operative Therapy** Incomplete Ligament Tear and Non-Displaced Bony Avulsions	**Post-Operative Therapy** Complete Ligament Tear and Displaced Bony Avulsions
1	• Thumb spica plaster or thermoplastic splint immobilization. Immobilization of wrist and IP joints may be needed *(may continue* splinting until *week 6).*	• Same as Non-Operative Therapy *(may continue splinting until week 6).*
2		
4	• Cut splint down to exclude wrist, begin splinting schedule: wear during sleep, in crowds, and other tenuous situations. • Initiate AROM of MCP joint.	• If surgeon removes cast, K-wire, and pull out wire, apply hand-based splint. • Full-time splint, except during supervised ROM of CMC and wrist joints.
5	• Begin and progress PROM of the thumb MCP joint.	
6		• Begin AROM of MCP joint. • Protect lateral stability. • Splint schedule: during sleep, in crowds, tenuous situations.
7		• Begin gentle PROM of MCP joint.
8	• Begin and progress strengthening on the ulnar border during grip and pinch. • Strengthen the locking of the thumb around a 6–8cm diameter cylinder. • Strengthen muscles for lateral and tip pinches.	• Begin and progress dynamic splinting of the MCP joint as indicated.
10	• Begin unrestricted use. • Decision of when to allow patients to return to sports is dependent on estimated healing of the injury, pain, swelling, strength, and the ability to perform the specific requirements of their sport. **Generally, it is recommended that patients participate in NO high-risk sports activities (i.e., football, basketball, handball, soccer, softball) for 6 months following injury. ****	• Begin and progress strengthening on the ulnar border during grip and pinch. • Strengthen the locking/positioning of the thumb around a 6–8cm diameter cylinder.
12-16		• Strengthen muscles for lateral, tip, and three jaw pinch. • Begin unrestricted use. • May protectively tape during sport activities.
** It is possible to resume sports activities sooner *IF* athletic tape is available for use by the inmate; however, athletic tape is not consistently available to inmates throughout the BOP for security reasons. Even so, the strength of the healed ligament improves with time so that it may be easier to have a significant re-injury if it has been less than 6 months.		

Management of Distal Radius Fractures

Note 1- Splint/cast does not need to be removed if patient is not experiencing a problem.

Note 2- If snuffbox tenderness exists without apparent associated fracture, proceed to "Management of Acute Scaphoid Fracture" algorithm.

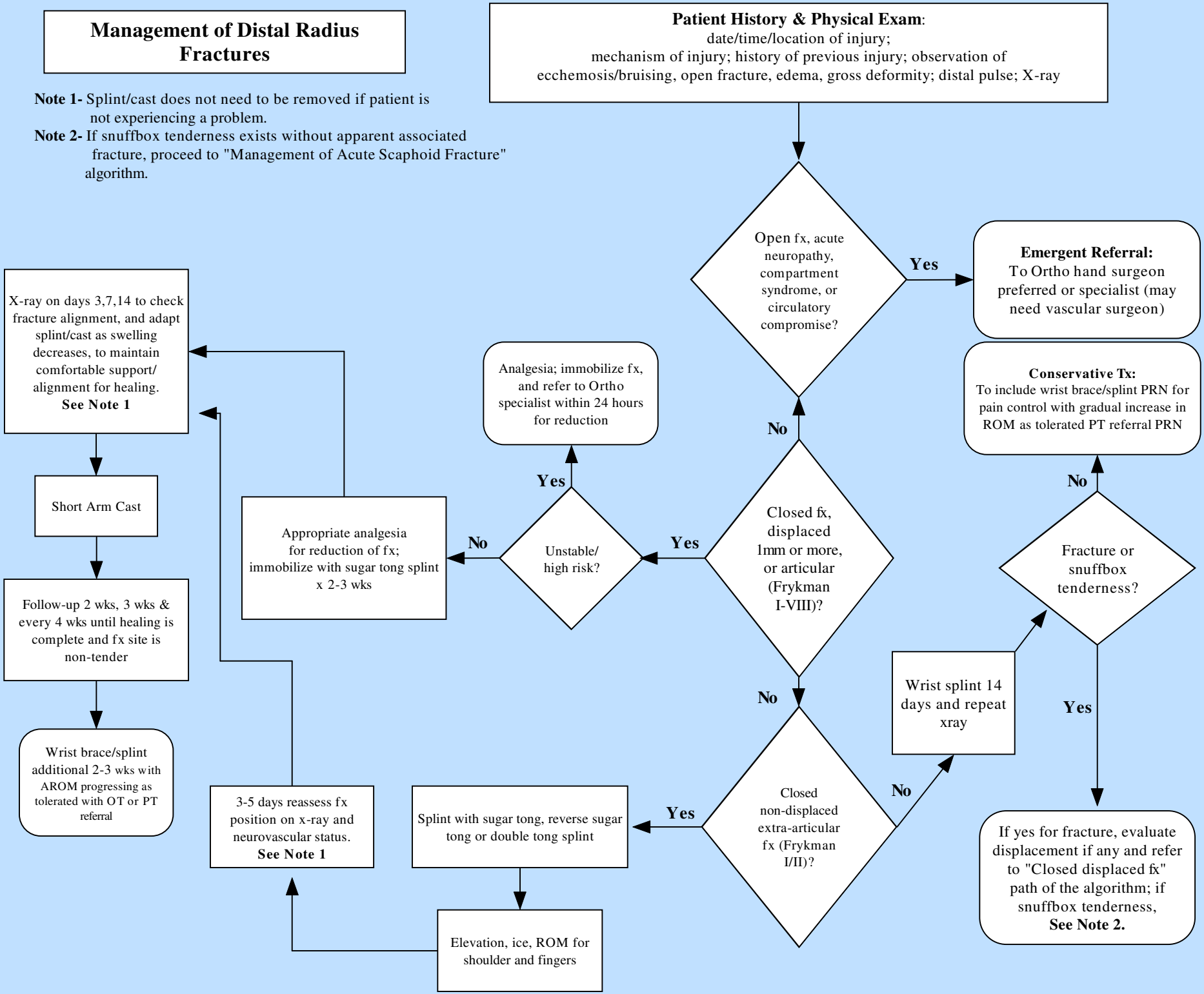

Federal Bureau of Prisons
Clinical Practice Guidelines

MANAGEMENT OF DISTAL RADIUS FRACTURES

December 2012

PURPOSE

The Federal Bureau of Prisons Clinical Practice Guidelines for Management of Distal Radius Fractures provide evidenced-based recommendations or guidelines for the outpatient management of federal inmates with acute distal radius fractures, including open, closed displaced, and closed non-displaced fractures.

This evidence-based protocol is designed as a guide so that the front-line clinician can manage acute hand injuries with the confidence inherent in standardized practice. A thorough examination and close, consistent follow-up care are essential for achieving satisfactory outcomes.

REFERENCES

American Academy of Orthopedic Surgeons. Distal Radius Fracture. http://orthoinfo.aaos.org/topic.cfm Copyright 2007. Accessed January 23, 2011.

eMedicine. Radius, Distal Fractures. http://emedicine,medscape.com/ article/398406. Updated August 18, 2009. Accessed January 23, 2011.

Up to Date. Distal Radius Fractures in Adults. http://www.uptodate.com/home/store.do. Updated October 14, 2010. Accessed January 26, 2011.

WebMD. Colles' Fracture (Distal Radius Fracture or Broken Wrist). http://www.webmd.com/a-to-z-guides/colles-fracture? Updated February 17, 2010. Accessed January 23, 2011.

Dell PC, Dell RB. Management of carpal fractures and dislocations. In: Mackin EJ, Callahan AD, Skirven TM, Schneider LH, Osterman AL, Hunter JM, Robert RR, eds. Rehabilitation of the Hand: Surgery and Therapy. Vol 1. 5th ed. St. Louis, MI: Mosby; 2002: 1171-1173.

DEFINITIONS

- ***Distal radial ulnar joint (DRUJ):***
  The distal portions of the ulna and radial bones are the ends closest to the hand. The distal radio-ulnar joint (DRUJ) is the joint where the radius and the ulna bones connect to each other near the hand. This joint allows the hand to turn palm-up (supination) or palm-down (pronation). Instability of the DRUJ results in poor function and a decrease in range of motion, and is often painful.

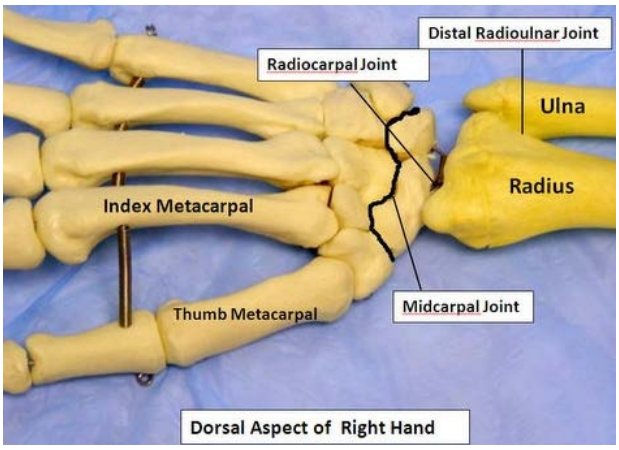

- ***Distal radius fracture:***
  The radius is the larger of the two forearm bones located on the thumb side, and is one of the most commonly fractured bones. Distal radius fractures are generally caused by a *fall on an outstretched hand* (FOOSH). The fracture is almost always within an inch of the wrist joint, and may extend into the joint.

Colles' Fracture

Colles' Fracture

Two common eponyms associated with distal radius fractures are Colles' and Smith's.

- ***Colles' fractures*** involve dorsal displacement of the distal radius fragment.

- ***Smith's fractures*** involve palmar displacement of the distal radius fragment.

- ***Comminuted fracture:***
  The bone is broken into several or many small pieces.

- ***Extra-articular fracture:***
  The fracture line does not extend into the joint.

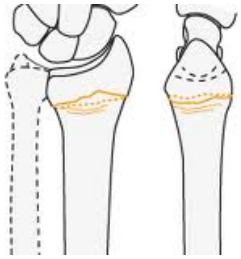

- ***Frykman classification of distal radius fractures:***
  Distal radius fractures can be described using either a fragment-specific classification or the standard Frykman classification. The Frykman classification system divides the fractures into four main groups, based on joint involvement. **Within each major grouping, fractures with even numbers involve a concomitant ulnar styloid fracture.**

  Frykman Categories:
  - ***Types I/II:*** Completely extra-articular; complications are uncommon once anatomic alignment has been achieved.
  - ***Types III/IV***: Extend into the radiocarpal joint.
  - ***Types V/VI:*** Extend into the distal radioulnar joint (DRUJ).
  - ***Types VII/VIII:*** Involve both radiocarpal and DRUJ articular surfaces and are highly unstable.

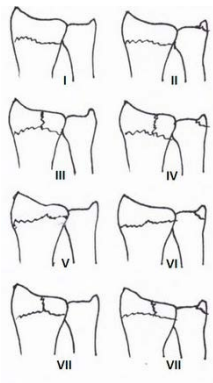

- ***Intra-articular fracture:***

  The fracture line does extend into the joint; this is the more serious type of fracture.

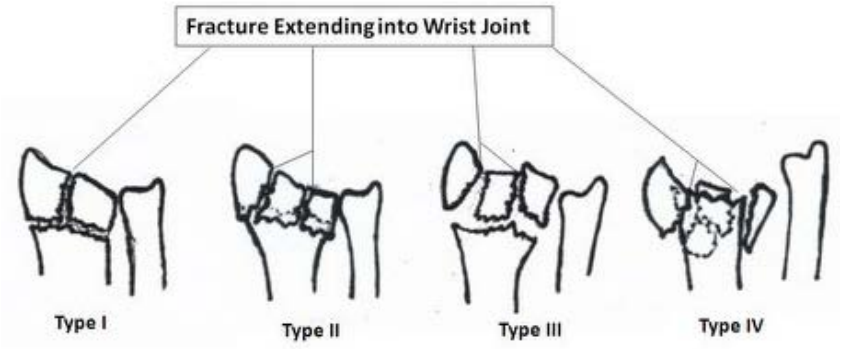

INTRA-ARTICULAR WRIST FRACTURE

- ***Fracture instability:***

  Loss of radiographic alignment after initial closed reduction and splinting. An unstable fracture is already displaced or is likely to get displaced, rotated or shortened during the healing of the bone.

- ***Fracture stability:***

  A stable fracture is non- or minimally-displaced and in good functional position to heal. The broken ends of the bones meet up correctly and are aligned. In a stable fracture, the bones usually stay in place during the healing process.

- ***Less-rigid immobilization:***

  Any type of wrap, brace, or splint that either incompletely immobilizes the wrist or is intended to be removed by the patient.

- ***Fracture malunion:***

  A fracture that heals poorly or in an incorrect position.

- ***Rigid immobilization:***

  Any form of immobilization that is firm (e.g., plaster, fiberglass) and not intended for self-removal.

  Sugar tong splint (left) and Double sugar tong splint (right):

Note: components of each of these splints are then held in place with coban wrap, Ace bandage, or other similar material.

- ***Three-point contact cast:***

  The application of 3-point contact by molding of the cast, as shown, will serve to resist late redisplacement. The wrist should be placed in 15° of flexion, 15° ulnar deviation, and 20° pronation.

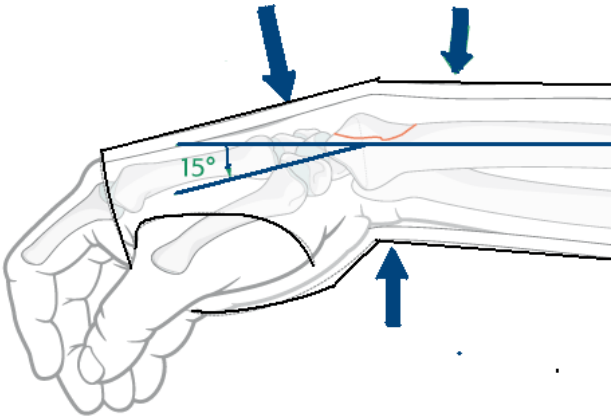

- ***Ulnar styloid fracture:***

  About half of distal radius fractures occur in association with an ulnar styloid fracture. The ulnar styloid is at the end of the other forearm bone, the ulna. While distal radius fractures usually require casting or surgery, the ulnar styloid is seldom addressed in treatment.

PROCEDURES

1. Introduction:

Acute distal radius fracture results in pain, tenderness, swelling, and potential deformity of the affected wrist and hand. Patients may be faced with significant pain and diminished function, or a clinically significant deformity, if fracture healing is delayed. Also, there are known complications in the treatment of distal radius fracture. The recovery period for distal radius fracture can be substantial, and the impact of the method of stabilization on activities and daily living can be significant. The goals of treatment are pain relief and maintenance of the patient's functional status.

- **Rigid immobilization is preferred to removable splints when using non-operative treatment** for the management of distal radius fractures. The use of removable splints or any other less-rigid immobilization is recommended only as a last option when treating distal radius fractures.
- **X-rays: Distal radius fractures that are treated non-operatively should have a follow up radiograph performed within 3 days after casting and then with weekly radiographic evaluation for the first 3 weeks after injury, then at 6 weeks after the injury, and then every 4 weeks until the conclusion of healing.**
- **Redisplacement during non-operative treatment of distal radius fractures may result in symptomatic malunions.** Therefore, it is highly recommended that routine follow-up occur to ensure that adequate fracture reduction is maintained.
- **All patients with distal radius fractures should receive a post-reduction PA and true lateral x-ray of the wrist to assess DRUJ alignment.** This is necessary because the DRUJ is often injured together with distal radius fractures. DRUJ injuries are treatable if caught early. A comparison view of

the other wrist (in the same position) may be helpful in assessing proper position of the DRUJ.

- **All patients with distal radius fractures and unremitting pain during follow-up should be re-evaluated for undiagnosed conditions or loss of fracture alignment.** The pain associated with a distal radius fracture should typically diminish after standard treatment protocols. The patient's reports of unremitting pain during the early treatment period may signal a concomitant condition that requires further evaluation.

  Every patient in the treatment of distal radius fracture should report their progress in recovery. When pain levels do not decrease as expected, it is appropriate to evaluate the patient for causes of pain.

- **CAUTION/WARNING:** All patients get swelling of the wrist, and subsequently the fingers, after forearm/wrist/hand fracture. Many patients do not adequately elevate the hand/wrist, which can increase swelling, as well as pain (typically throbbing) and finger stiffness. **The only way to adequately elevate the wrist, while sitting or standing, is to rest the hand on top of the head so the that the wrist and elbow are above the heart (see below).** Walking around with the forearm in a sling is not adequate elevation, especially within the first 2 to 5 days after the injury.

Proper Elevation of the Wrist

- **It is strongly recommended that patients perform active finger motion exercises following diagnosis of distal radius fractures.** Hand/finger stiffness is one of the most functionally disabling adverse effects after distal radius fractures. Stiffness of the fingers can result from a combination of factors including pain, swelling, obstruction by splints or casts, and apprehension or lack of understanding by the patient. Finger stiffness can be very difficult to treat after fracture healing, requiring multiple therapy visits, and possible additional surgical intervention. Instructing the patient at the first encounter to move their fingers regularly and through a complete range of motion (in addition to proper elevation) may help to minimize the risk of this complication. Finger motion does not have any adverse

effects on an adequately stabilized distal radius fracture with regard to reduction or healing. This is an extremely cost-effective intervention as it does not require any pharmaceutical intervention or additional visits, while making a significant impact on patient outcome. **Although finger stiffness is a critical adverse effect of distal radius fractures and directly impacts patient outcome, the effects of early active motion can greatly reduce this complication.**

2. Emergent Conditions:

Recognition of emergent conditions and the decision of whether to perform a fracture reduction comprise the most important steps in the acute management of distal radius fractures.

- **If significant nerve injury (e.g., paralysis, severe weakness, or severe numbness) or vascular compromise is present, immediate reduction of the displaced fracture, with analgesia, is necessary to attempt to alleviate these symptoms.** These symptoms may signal the onset of a **compartment syndrome**. Persistent symptoms despite reduction mandate emergent consultation with the appropriate surgical specialist. Compartment syndrome is an emergency requiring immediate surgical release.

- **Displaced, angulated, or malrotated fractures should also be stabilized immediately.** Since swelling can progress rapidly, the best opportunity for closed reduction of these fractures is within the first few hours following injury.

- **Open Fractures:** A fracture, with a soft-tissue wound that communicates with the fracture site (*open fracture*) also constitutes an emergent condition. **Any wound that is not a superficial abrasion needs to be carefully evaluated with the assumption that an open fracture exists until proven otherwise.**

  Open fractures require immediate irrigation, debridement, and fixation in the operating room. **If there is going to be a delay of more than 3 hours, the wound should be irrigated and covered with betadine gauze. Antibiotics should be started.**

- **Superficial lacerations are irrigated and sutured with loose approximation of the skin edges to allow for swelling.** The wound is then dressed with an absorbent, non-constrictive dressing.

- **Unstable or displaced fractures may also require surgical management.** Intra-articular fractures should be referred to an orthopedist. Provisional immobilization with splinting should be initiated by the clinician.

3. Non-Emergent Conditions:

Should no emergent condition exist, immediate reduction is not required, and appropriate treatment depends upon the type of fracture.

a. Closed Displaced Fracture (Frykman I-VIII):

- Displaced fractures **with neurovascular compromise** warrant an immediate attempt at closed reduction.
- Prompt closed reduction by an experienced clinician is appropriate, but not required, for displaced fractures **without neurovascular compromise or radiographic evidence of instability**. If a clinician capable of performing a reduction is unavailable, the provider may immobilize the fracture and manage the patient's pain appropriately.

  It is highly recommended that the patient be monitored every 3 to 4 hours for any changes in neurovascular status, especially if the patient cannot be seen by an orthopedist or other specialist until the next day. When practical, the patient should not be discharged until follow-up care with an orthopedist has been arranged.
- Substantial soft tissue swelling often accompanies displaced fractures, so splinting is recommended for post-reduction immobilization. The application of a circumferential cast in the acute setting increases the risk of distal ischemia and carpal tunnel syndrome, and therefore should not be performed.
- During the first several days following injury, the patient should elevate the arm, apply ice frequently to areas of increased swelling not covered by hard splinting or casting material (while keeping the splint dry), begin active range of motion of the shoulder and fingers, and use analgesics as needed. Opioids may be necessary, and a short course of non-steroidal anti-inflammatory drugs (NSAIDs) may also be used.
- Once reduction is achieved, it is suggested that patient remain in the initial sugar tong splint for 2 to 3 weeks. The U-shaped part of the splint wraps around the elbow to minimize forearm rotation while maintaining the desired pronation or supination, according to the fracture type. The sugar tong splint also immobilizes the distal radioulnar joint (DRUJ), and splinted patients experience less pain than patients immobilized in a short arm cast.
- Radiographs are taken in the sugar tong splint within 3 days of casting and then every 7 days following reduction, for 3 weeks. This enables the clinician to quickly detect any loss of position and to assess the acceptability of any

post-reduction movement or residual deformity. During the first 2 weeks, the initial splint should be adapted and molded as soft tissue swelling decreases. This is achieved by wrapping the splint tighter (may need to re-check in 3 to 4 hours to make sure that it is not overtightened) with elastic bandages at each follow-up visit. Adequate tightness and molding throughout the early post-reduction period reduces the risk of secondary displacement.

- At 2 to 3 weeks, the splint is changed to a short arm cast. Wrist immobilization continues in the cast for another three to 4 weeks. The clinician must take care to maintain three-point contact and to avoid inadequate or excessively bulky padding. At each visit, the clinician should assess fracture site pain, swelling, elbow and hand motion, and median nerve function. Radiographs should be obtained every week for the first 3 weeks and studied for signs of dorsal displacement, palmar angulation, and radial shortening.
- Patients should be immobilized for 6 to 8 weeks, until there is evidence of radiographic healing and the fracture site is non-tender. At this point, the clinician can remove the cast and place the patient in a wrist brace. Complete healing generally occurs within 8 to 12 weeks. The shortest possible period of immobilization is preferred for older patients; prolonged immobilization can cause joint stiffness and significant loss of function.
- Once the cast is removed, patients should begin active range-of-motion exercises. Physical or occupational therapy may be needed to achieve acceptable motion, but most patients require only a single session of instruction. Older patients and those with more complicated fractures requiring prolonged immobilization may require more extensive rehabilitation.

b. <u>Non-Displaced Extra-Articular Fractures (Frykman types I/II)</u>:

- These fractures are relatively stable and can be treated with a well-molded sugar tong, reverse sugar tong, or double sugar tong splint. The application of a circumferential cast in the acute setting increases the risk of distal ischemia and carpal tunnel syndrome, and therefore should not be performed.
- Proper positioning within the splint has the elbow flexed to 90 degrees and the arm in neutral position (i.e., thumb-up position and without wrist flexion or extension). During the first several days following injury, the patient should elevate the arm (emphasize proper way to elevate), apply ice to the fracture frequently (while keeping the splint dry), begin active range of motion of the shoulder

and fingers, and use analgesics as needed. Opioids may be necessary; a short course of non-steroidal anti-inflammatory drugs (NSAIDs) may also be used.

- Patients are seen 3 to 5 days following injury to monitor swelling and to allow swelling to subside. The clinician should remove the splint, assess neurovascular status, and obtain radiographs of the arm out of the splint to confirm that there is no loss of position.
- If the fracture remains non-displaced or minimally displaced, the clinician applies a short arm cast. Patients should be seen in follow-up every 3 weeks thereafter until healing is complete. Radiographs are taken at the initial post-casting visit, at 2 weeks, and then sometime between 4 to 6 weeks after injury to confirm proper alignment.
- The patient's wrist and forearm should remain immobilized until there is evidence of radiographic healing or the fracture site is non-tender, generally 4 to 6 weeks post-injury. At this point, the patient can use a wrist brace in lieu of a cast. Complete healing usually requires 6 to 8 weeks.
- **For patients over 60 years of age, the period of immobilization should be kept to a minimum to avoid post-immobilization stiffness.** Early transition to a wrist splint may be helpful depending on fracture stability. In one randomized trial, patients treated with a wrist splint were more satisfied and regained function sooner than patients immobilized in a cast.

4. Clinical Pathway:

See attached algorithm for *Management of Distal Radius Fractures*.

Management of Closed Fist/Fight Bite Injury

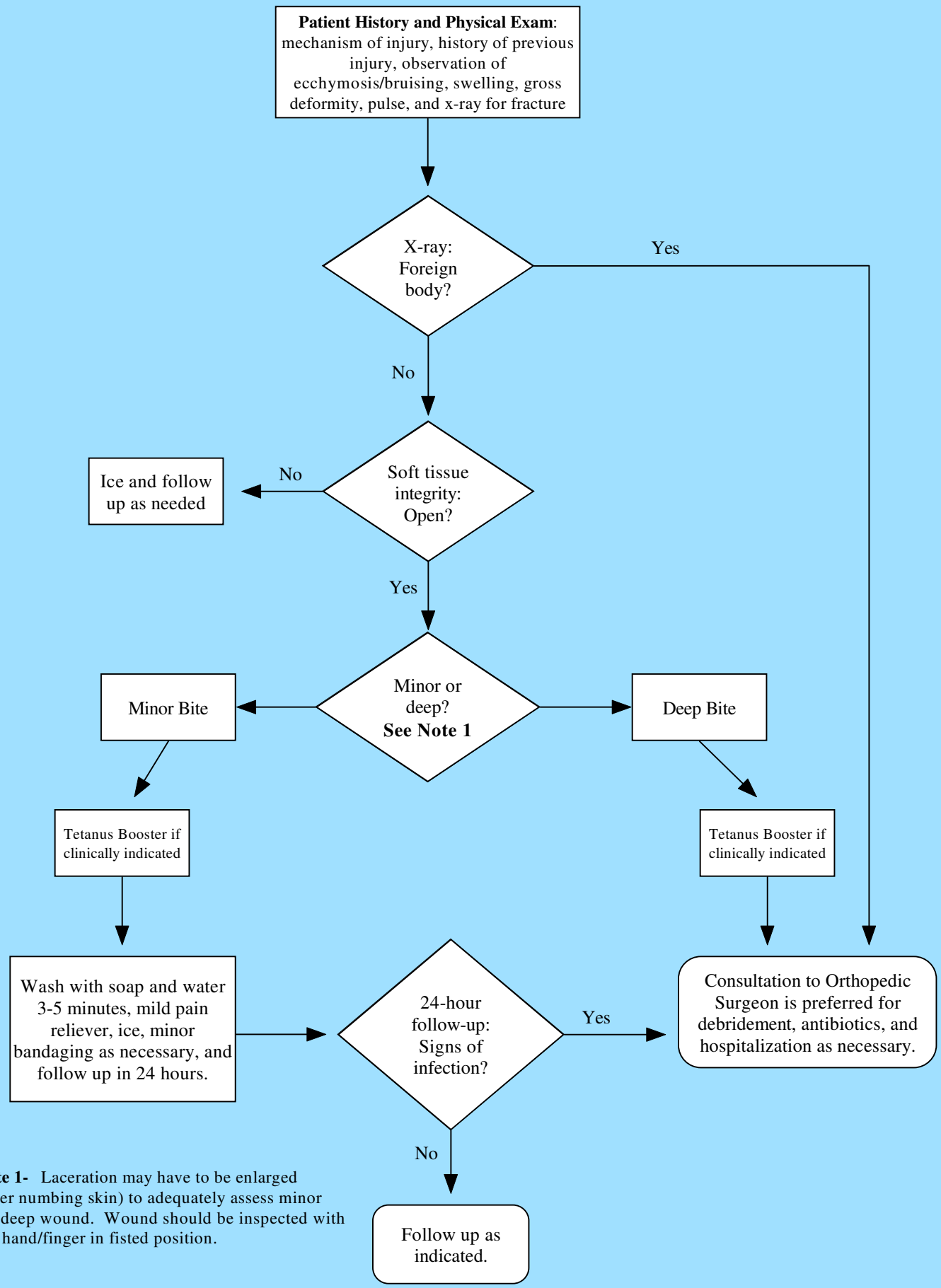

Note 1- Laceration may have to be enlarged (after numbing skin) to adequately assess minor vs. deep wound. Wound should be inspected with the hand/finger in fisted position.

Federal Bureau of Prisons
Clinical Practice Guidelines

MANAGEMENT OF CLOSED FIST/FIGHT BITE INJURY

December 2012

PURPOSE

The Federal Bureau of Prisons Clinical Practice Guidelines for Management of Closed Fist/Fight Bite Injury provide evidenced-based recommendations or guidelines for the outpatient management of federal inmates with acute closed fist injury.

This evidence-based protocol is designed as a guide so that the front-line clinician can manage acute hand injuries with the confidence inherent in standardized practice. A thorough examination and close, consistent follow-up care are essential for achieving satisfactory outcomes.

REFERENCES

eMedicinehealth. Human Bites. http://emedicinehealth.com/
Updated August 10, 2005. Accessed April 20, 2011.

Greater Chesapeake Hand Specialists (Bite Injuries – Human Bites).
http://www.chesapeakehand.com/tabid/20343/mid/38025.
Updated February 10, 2011. Accessed April 20, 2011.

Perron AD, Miller MD, Brady WJ, et al. Orthopedic pitfalls in the ED: fight bite. *Am J Emerg Med*. 2002;20(2):114-117.

DEFINITIONS

Fight Bite: Closed fist injury to the hand where the hand is injured while striking the teeth of another person. This can result in a whole range of injuries from minor bruising to larger lacerations and injuries to the bones, joints, ligaments, tendons, nerves, blood vessels, and muscles.

Minor Bite: A bite that just causes bruising or only scrapes the top layer of skin and will not require much more than cleaning with soap and water, ice, and mild pain medication such as acetaminophen. A tetanus shot may be needed if the skin is broken. Antibiotics are usually not necessary for this type of bite.

Deep Bite: Any bite that bleeds a lot or appears to be more than a scrape needs thorough cleaning and examination. Besides giving a tetanus shot, the doctor will generally numb these bites with local anesthetic, examine the wound, and thoroughly clean the wound (usually irrigation with a large amount of clean water and occasionally a small amount of antiseptic solution to decrease the risk of infection).

PROCEDURES

1. Introduction:

Fight bite wounds have the highest incidence of complications of any closed fist injury and any type of bite wound. The high infection and complication rate is due to two factors:

(1) The high oral bacterial count of the human mouth with increased potential for the spread of the bacteria in the wound once the fingers are extended after contact, and

(2) The avascular nature of the extensor tendon and the joint, leading to decreased ability to fight infection.

These factors increase the opportunity for bacteria to multiply and spread, leading to the involvement of soft tissues, joint space, tendon sheath, and extensor tendons on the back of the hand and wrist. The most common bacterial infections are caused by: (1) *Staphylococcus aureus,* (2) *Streptococcus sp,* (3) *Corynebacterium sp,* and (4) *Eikenella corrodens.* Human bites have also been documented to transmit hepatitis B and C, actinomycosis, syphilis, herpes, and tetanus.

These injuries typically occur over the back of the hand with the third, fourth, or fifth metacarpophalangeal joints (MCPJ or knuckles) most commonly involved. Because there is minimal skin to protect the joint or the underlying ligaments, synovium, and cartilage, these injuries have an increased risk for deep infection. The classic injury pattern is tooth penetration of the back of the hand over the third knuckle/joint, with opening of the soft tissue at this site allowing oral bacteria to penetrate the wound and possibly the joint. This bacterium is then dragged deeper into the hand along the extensor tendon when the hand is opened after the contact.

ADVISORY: It can be difficult to assess tendon and joint damage after an injury unless the hand and fingers are placed in the same clenched fist position that they were in at the time the injury occurred.

2. Non-Operative Management of the Fight Bite:

Patients may present acutely for care, before clinical infection occurs, but are typically seen once an infection process has begun (5-7 days) after the injury. For acute presentation, symptoms can be subtle, including abrasions or seemingly superficial lacerations over the MCP joint, mild erythema, and signs of cellulitis.

- Be sure to **(1)** clean the wound thoroughly with **anti-bacterial** soap and water for 3–5 minutes, **(2)** provide a tetanus shot if needed, and **(3)** use Tylenol or another NSAID along with ice for pain relief. **(4)** Follow up in 24-48 hours to reassess for signs of early infection.
- **Minor bites**: When acute, some signs and symptoms of a minor bite can be a skin break or raw appearance with the top layer of skin (epidermis) missing, **without penetration through the dermis.**

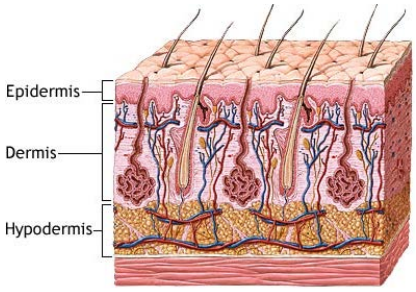

- **Always assume that oozing of clear fluid is a sign of compromise of the joint capsule, a serious condition that requires an urgent consult to an orthopedic surgeon or specialist until proven otherwise.**

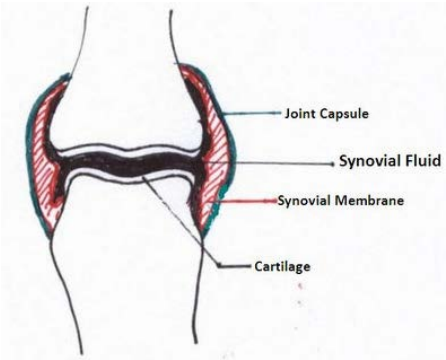

- **If you see any signs of infection on follow-up examination, urgent consultation with an orthopedic surgeon or hand specialist is recommended.** Signs of infection include, but are not limited to: increased warmth, redness, fever, increased pain or tenderness (especially with passive motion of the affected finger), increased swelling, purulent discharge, or swollen lymph nodes on the same side as the bite. Again, with **any sign of infection**, a referral to an orthopedic surgeon or specialist for further follow up is highly recommended.

3. Indications for Consultation to Emergency Room and/or Orthopedic Hand Services for the Fight Bite:

- Any bite that bleeds a lot or appears to be more than a scrape needs thorough cleaning and examination. The emergency department is well-equipped to do this by having special equipment and lighting. The doctor may have to numb the area with medicine to rule out tendon laceration and/or contamination of the joint before the wound is assessed. The bite may also need to be debrided during cleaning with consideration for antibiotics and possible hospitalization.
- **ADVISORY: If the inmate cannot be seen within 2-3 hours after the injury, then the wound should be irrigated by a member of the primary care team and antibiotics started until the inmate can be taken out for consultation.**
- **Deep bites:** Beware of the following signs and symptoms which necessitate referral to an orthopedic surgeon or specialist. **When acute some signs and symptoms of deep bites can be:**
  - break in the skin
  - bleeding at bite site
  - puncture wound without bleeding
  - oozing of clear fluid, unless verified that it IS NOT synovial fluid
  - any signs of infection such as heat/increased warmth, redness, swelling, and increased pain (particularly with passive motion of the involved finger)

4. Non-Operative versus Consultative Treatment:

Treatment for the human bite can range from just ice for swelling to a trip to the operating room, depending on the bite. Since even minor bites are easily infected and can become very serious, early treatment is important to give the best chance at preventing infection. Thus, **"if in doubt, consult it out."**

5. Clinical Pathway:

See attached *Management of Closed Fist/Fist Bite Injury* algorithm.

Management of Tendon Injuries of the Finger

Patient History and Physical Exam:
Mechanism of injury, history of previous injury, perfusion, motion, sensation, observation of ecchymosis/bruising, swelling, cascade and posture of hand and affected finger

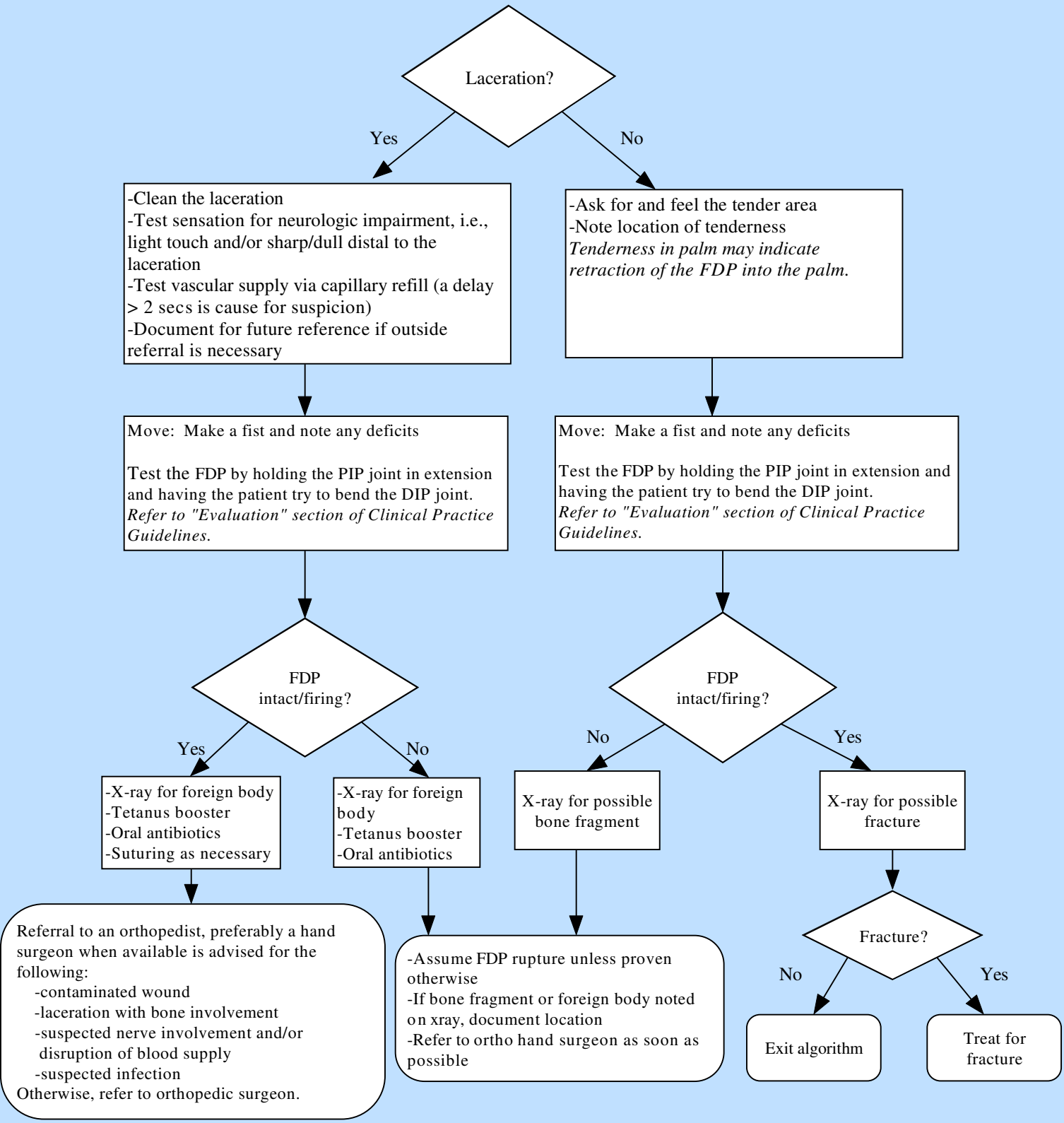

Note: When a question exists about the extent of the injury, it is advisable to send the patient promptly for at least one evaluation to ensure that no associated structural damage has occurred. Otherwise, follow-up care should occur within 24 hours and then again within one week of the injury. Sutures should be removed 2 weeks after placement if used.

Federal Bureau of Prisons
Clinical Practice Guidelines

MANAGEMENT OF TENDON INJURIES OF THE FINGER

December 2012

PURPOSE

The Federal Bureau of Prisons Clinical Practice Guidelines for Management of Tendon Injuries of the Finger provide evidenced-based recommendations or guidelines for the outpatient management of federal inmates with acute tendon injuries of the finger.

This evidence-based protocol is designed as a guide so that the front-line clinician can manage acute hand injuries with the confidence inherent in standardized practice. A thorough examination and close, consistent follow-up care are essential for achieving satisfactory outcomes.

REFERENCES

Evans NA, Stanish WD. The basic science of tendon injuries. *Current Orthop.* 2000;14:403-12.

Hayton M. Assessment of hand injuries. *Current Orthop.* 2002;16:246-54.

Leddy, JP, Packer JW. Avulsion of the profundus tendon insertion in athletes. *J Hand Surg.* 1977;2:66-9.

Dell PC, Dell RB. Management of carpal fractures and dislocations. In: Mackin EJ, Callahan AD, Skirven TM, et al, eds. *Rehabilitation of the Hand: Surgery and Therapy, Vol 1*. 5th ed. St. Louis, MI:Mosby; 2002: 1171-1173.

DEFINITIONS

- ***Avulsion:***
  An injury where the tendon is forcibly detached or torn away at its insertion.

- ***Cascade of hand:***
  The natural resting position of the hand should be closely observed to determine whether the normal composite cascade of the fingers has been disrupted. In the uninjured hand, the composite flexion of the fingers increases from the radial or thumb side to the ulnar side. The finger with a tendon disruption rests in a more extended position. If only the FDP tendon has been lacerated, the flexion of the MCP and PIP joints may be within the normal cascade, but the DIP will be extended. (See photographs on next page.)

Normal cascade of the hand versus abnormal hand postures due to tendon injury.

- ***Flexor tendon zones:***
  Many factors influence recovery following flexor tendon injury – location of injury, in particular. Flexor tendon injuries are traditionally described as occurring in one of five zones. **Zone 1** contains only the **flexor digitorum profundus** (FDP). The functional impact of a zone 1 tendon injury is an inability of the patient to flex the distal joint of the affected finger.

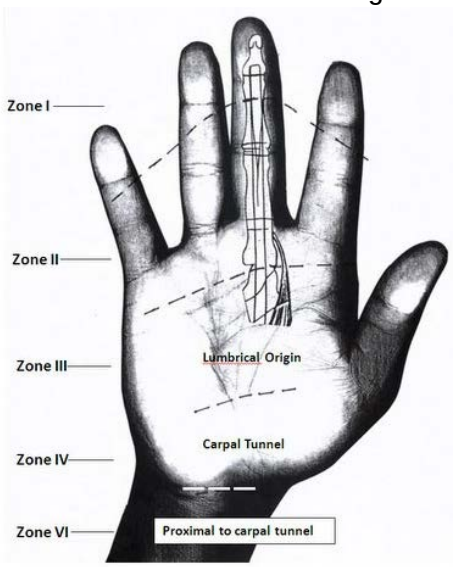

- ***Tenodesis effect:***
  In a **normal hand** with tendon intact, passive *flexion* of the wrist will result in concomitant extension of the fingers; passive *extension* of the wrist will result in a natural closing of the fingers.

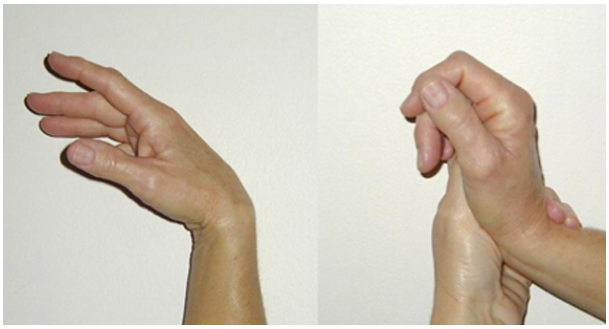

PROCEDURES

1. Introduction:

Injuries to the flexor tendons of the hand are common. With injuries that involve flexor tendons, fully defining the pathology is especially important. Clinical examination is an essential part of the assessment of any patient who presents with a hand injury. Identification of damaged structures is best performed by an orthopedic surgeon, as several studies have shown underdiagnosis of hand injuries when examined by emergency department staff alone.

Flexor tendon lacerations typically are sustained while a person is either holding a knife or attempting to wrest a sharp object from someone else with the finger in a flexed position. Frequently with this mechanism of injury, there is an associated digital nerve or artery laceration.

An avulsion or laceration of the flexor digitorum profundus (FDP) tendon is often overlooked by the patient or dismissed by the provider as a “sprained” or jammed finger, resulting in a delayed diagnosis. The ring finger is most often involved, and the injury is classically seen in football or rugby players whose fingers are caught in the opponent’s jersey, during which time the fingers are forcibly extended while maximal active contraction of the FDP tendon is occurring.

There are three (3) types of avulsion of the FDP tendon insertion:

- In a ***Type I*** profundus avulsion, the tendon retracts into the palm with loss of its blood/nutritional supply. This type of injury usually results in exquisite tenderness in the palm of the hand at the distal palmar crease.
- ***Type II*** profundus avulsion is most often seen, with the end of the injured tendon resting at the proximal interphalangeal (PIP) joint level, its blood supply mostly intact.
- **Type III** avulsions are associated with a fracture fragment caught in a pulley just below the distal interphalangeal (DIP) joint of the affected finger.

Whether the tendon is lacerated or avulsed, surgical reattachment of the tendon ideally should be performed within 7 days, before permanent contracture happens. After 10 days to 2 weeks, the tendon is normally retracted, scarred down, and swollen.

2. Evaluation:

The clinical presentation of FDP injuries is remarkable for partial or complete loss of active flexion of the distal joint of the affected finger. In recent avulsions, the patient presents with pain at the DIP joint. Pain is intense along the flexor tendon, radiates to the palm, and can even be experienced in the forearm.

Palpation causes pain, and sometimes ecchymosis/bruising is found at the finger. Active flexion of the DIP joint is impossible. See below:

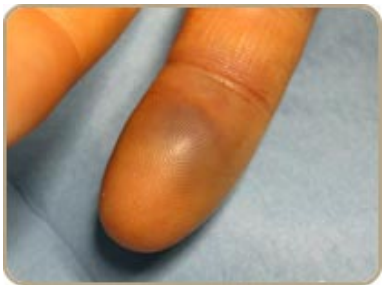

To isolate and test the FDP tendon, hold the PIP joint of the affected finger in extension and have the patient attempt to actively bend the DIP joint. See below:

All suspected injuries to the profundus tendon should have x-rays taken to determine if there is bony involvement and to rule out a foreign body such as glass with lacerations. In the event that the tendon has been lacerated and at risk for contamination, a tetanus prophylaxis or a booster is given. Broad spectrum antibiotics are also administered. With open wounds, irrigation of the wound is completed along with suturing of the skin.

An assessment of perfusion is performed by assessing capillary refill of the nailbed. **Capillary refill that is delayed more than 3 seconds is indicative of a vascular injury.** Neurologic

status can be quickly assessed using reported perception of light touch and/or sharp/dull. A clean, bulky dressing is applied that includes the forearm and entire hand.

3. Indications for Consultation by Orthopedic Hand Services:

Any suspected tendon injury should be referred to an orthopedic surgeon as quickly as feasible, so that a prompt repair of the tendon(s) can be initiated.

4. Clinical Pathway:

See attached algorithm for *Management of Tendon Injuries of the Finger*.

Management of Metacarpal Fractures

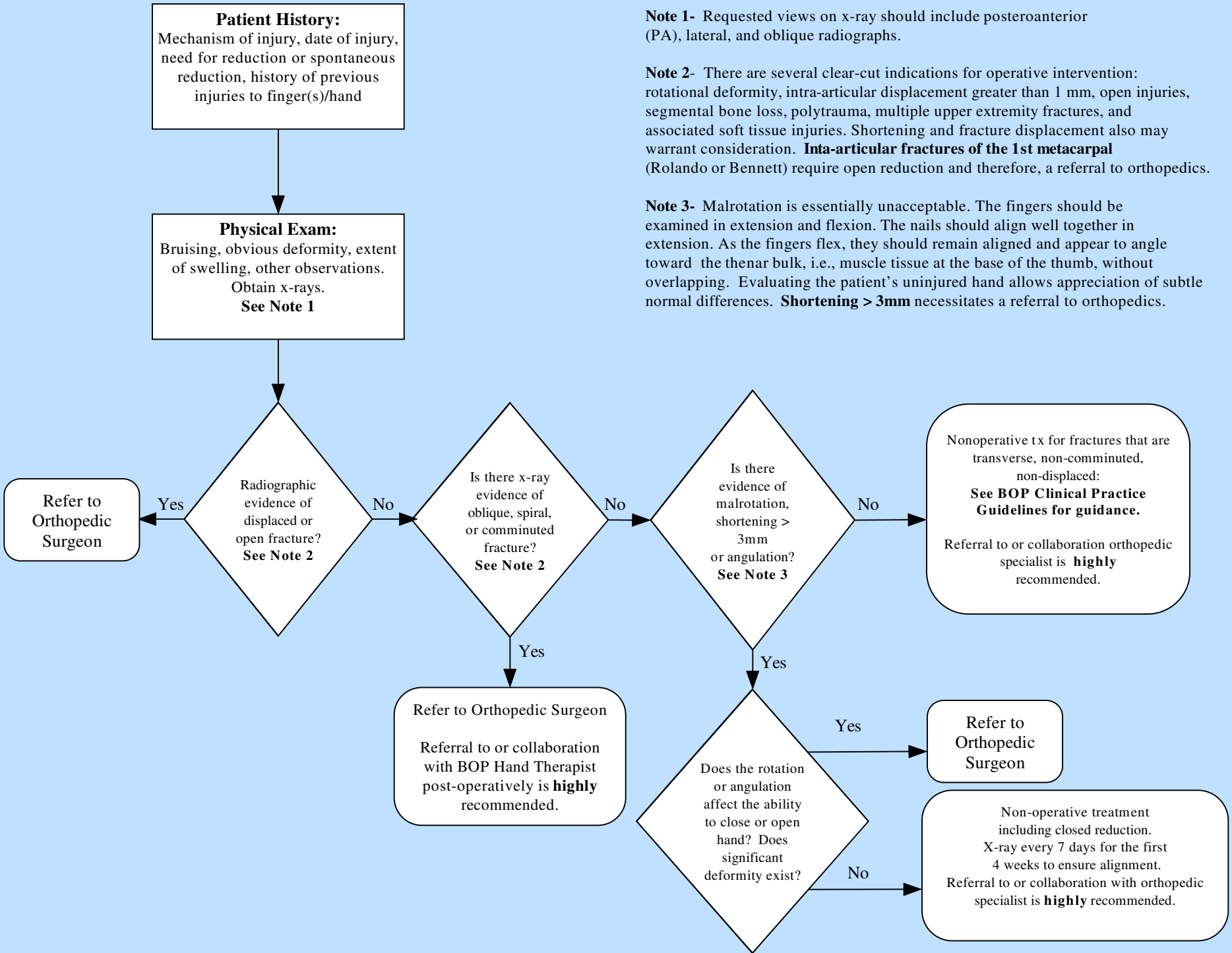

Note 1- Requested views on x-ray should include posteroanterior (PA), lateral, and oblique radiographs.

Note 2- There are several clear-cut indications for operative intervention: rotational deformity, intra-articular displacement greater than 1 mm, open injuries, segmental bone loss, polytrauma, multiple upper extremity fractures, and associated soft tissue injuries. Shortening and fracture displacement also may warrant consideration. **Inta-articular fractures of the 1st metacarpal** (Rolando or Bennett) require open reduction and therefore, a referral to orthopedics.

Note 3- Malrotation is essentially unacceptable. The fingers should be examined in extension and flexion. The nails should align well together in extension. As the fingers flex, they should remain aligned and appear to angle toward the thenar bulk, i.e., muscle tissue at the base of the thumb, without overlapping. Evaluating the patient's uninjured hand allows appreciation of subtle normal differences. **Shortening > 3mm** necessitates a referral to orthopedics.

Federal Bureau of Prisons
Clinical Practice Guidelines

MANAGEMENT OF METACARPAL FRACTURES

December 2012

PURPOSE

The Federal Bureau of Prisons Clinical Practice Guidelines for Management of Metacarpal Fractures provide evidenced-based recommendations or guidelines for the outpatient management of federal inmates with metacarpal fractures.

This evidence-based protocol is designed as a guide so that the front-line clinician can manage acute hand injuries with the confidence inherent in standardized practice. A thorough examination and close, consistent follow-up care are essential for achieving satisfactory outcomes.

REFERENCES

Atkison R. Athletic injuries of the hand. In: DeLee JC, Drez D, Miller MD, eds. *DeLee and Drez's Orthopaedic Sports Medicine*. 3rd ed. Missouri: WB Saunders; 2009.

Colditz J. Low-temperature thermoplastic splints/orthoses made by therapists: an overview of current practice. *O&P EDGE. October 2004.* Available at: http://www.oandp.com/articles/2004-10_03.asp

Hritcko, G. Digital fracture rehabilitation. In: Burke SL, Higgins JP, McClinton MA, Saunder RJ, Valdata L, eds. *Hand and Upper Extremity Rehabilitation: A Practical Guide*. St. Louis: Elsevier; 1993:547-560.

Lee S, Jupiter J. Phalangeal and metacarpal fractures of the hand. *Hand Clinics.* 2000;16(3):323-332, vii.

Purdy B, Wilson R. Management of nonarticular fractures of the hand. In: Hunter J, Schneider L, Mackin E, Callahan A, eds. *Rehabilitation of the Hand and Upper Extremity*. 5th edition. St. Louis: Mosby; 2002: 382-395.

Mastey R, Weiss A, Akelman E. Primary care of hand and wrist injuries. *Clin Sport Med*. 1997;16(4):705-724.

Schindeler-Grasse P, Jaffe R, Lundahl K. Fractures of the wrist and hand. In: *ASHT Test Prep for the CHT Exam.* Chicago: American Society of Hand Therapists; 2006:115-131.

Sytsma MJ, Bedi A. Bennett's fracture. SportsMD Website. Available at: http://www.sportsmd.com/Articles/id/%2017.aspx

DEFINITIONS

- ***Bennett's fracture:***
  A Bennett's fracture is an intra-articular fracture, or one that extends into the joint between the metacarpal and wrist bone ("trapezium"). This injury most often occurs in contact sports such as football, rugby, and boxing. Injury is most commonly seen in the dominant hand (2/3) and predominates in men at nearly a 10:1 ratio.

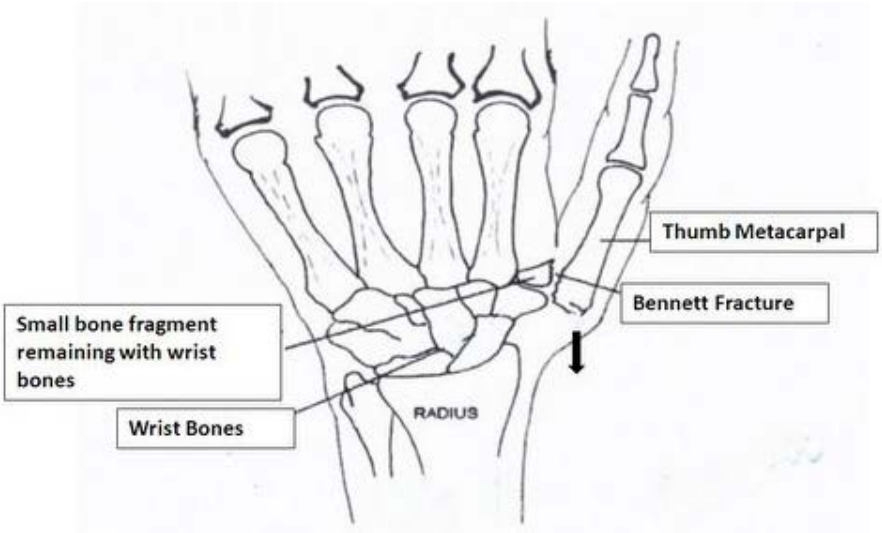

  Approximately 25% of metacarpal fractures occur in the thumb metacarpal. Of these fractures of the thumb metacarpal, 80% occur at the base (the end closer to the wrist). The Bennett's fracture is the most common type of fracture to the thumb metacarpal base.

- ***Boxer's fracture:***

  A fracture at the neck of the fifth metacarpal bone, often caused by a punch during a fight or boxing match, is the most common metacarpal bone fracture. The distal fracture fragment usually displaces in a volar, i.e., palmar, direction because of the shape of the bone and the pull of the muscles within the fisted hand.

- ***Fracture instability:***
  Loss of radiographic alignment after initial closed reduction and splinting.

- ***Fracture stability:***
  A stable fracture is non- or minimally-displaced and in good functional position to heal. The broken ends of the bones meet up correctly and are aligned. In a stable fracture, the bones usually stay in place during the healing process.

- ***Primary fracture healing:***
  Occurs with rigidly immobilized fractures; leads to direct bone healing with small callus.

- ***Secondary fracture healing:***
  Occurs from some motion at the fracture site; callus is stimulated by motion.

- ***Rolando fracture:***
  A "T" or "Y" shaped fracture of the first metacarpal base (thumb). It is similar to a Bennett fracture, except that a Rolando fracture is less common and the thumb is fractured into three or more pieces, as seen on radiographs. See below:

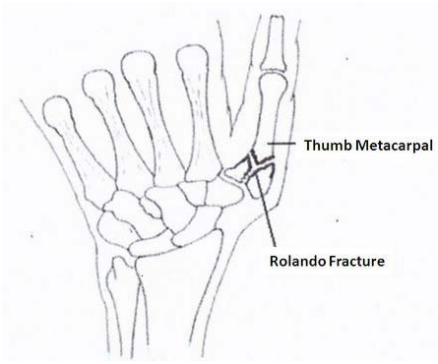

- ***Safe Position:***
  Immobilization with the MCPJ (metacarpal-phalangeal joint) in flexion (at least 70 degrees) to maintain collateral ligament and prevent shortening; PIPJ and DIPJ are positioned in extension, as shown below:

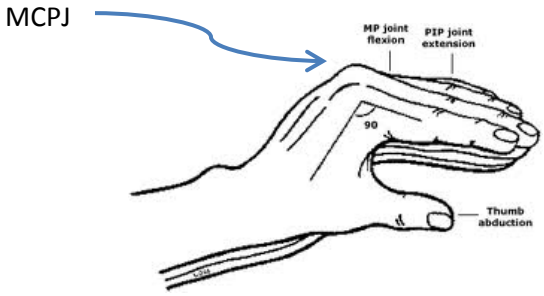

PROCEDURES

1. Introduction:

Typically given less credit than they deserve, metacarpal bones fill an essential role in the hand. They provide the hand space to grasp and to hold objects spanning the distance from the carpal bones to the fingers. Metacarpal fractures may result in loss of the patient's strength and motion, which can in turn lead to loss of function and some disability.

Return of hand function for daily activities is becoming an ever-increasing focus of acute care. Metacarpal fractures account for 30-40% of all hand fractures. More specifically, approximately 50% of metacarpal fractures occur within the fifth metacarpal. The neck of the metacarpal is the most frequent location of the fracture, which is often referred to as a Boxer's fracture.

The three areas for potential complication are rotational malalignment, dorsal apex angulation, and shortening:

- Five degrees of rotational change within the metacarpals can cause a 1.5 cm overlap when the patient attempts to make a fist (*see the picture on the next page*). The amount of acceptable angulation is dependent upon the location of the fracture. A 30-degree flexion angulation at the fifth metacarpal neck is well-tolerated.
- Angulation deformities may not be as functionally limiting as rotational problems, but patients are often dissatisfied with the appearance of a bump on the back of their hand. Generally, angulation closer to the neck (or distal end of the metacarpal) is better tolerated than angulation at mid-shaft of the metacarpal. Mid-shaft angulation will result in metacarpalphalangeal (MCP) joint hyperextension and a more obvious deformity.
- Shortening of up to 3mm is often well-tolerated, but greater than this amount may cause muscle imbalance and loss of function within the hand.

Subtle rotation can be detected with radiography, but may best be done by evaluating the patient's fist or semi-flexed fingers. If no rotation is present, all of the fingernails will be on the same plane and will be pointing towards the scaphoid bone. **It is important to use the opposite hand as a comparison because there is some variability in the amount of "normal" rotation/overlap of the fingers.** A patient should be referred to an orthopedic or hand surgeon if reduction is unsuccessful or if rotation is detected. (*See the illustration on the next page*.)

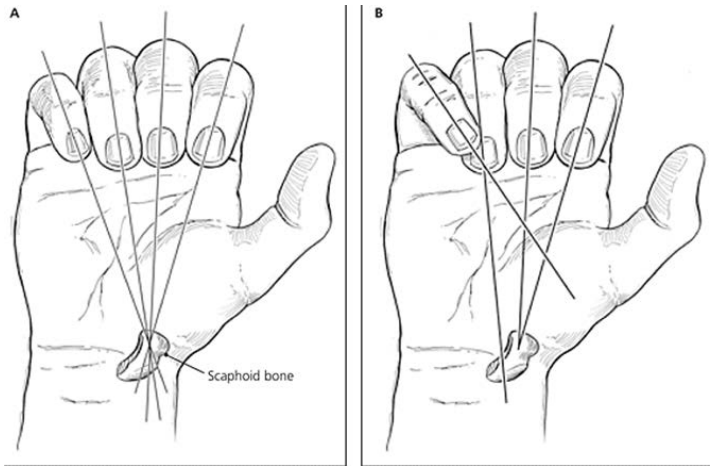

Detecting rotation in metacarpal fractures:
If no rotation is present, all fingertips will be on the same plane and pointing toward the scaphoid bone, as in the illustration on the left. The illustration on the right shows rotation.

Thumb metacarpal fractures are also quite common and account for 25% of all metacarpal fractures. The most common fracture of the thumb metacarpal is often referred to as a Bennett's fracture.

2. <u>Classification of Fracture</u>:

- Metacarpal fracture location is often referred to as ***base*** (nearest to wrist), ***shaft***, or ***neck*** (closest to digits).
- If the fracture line on x-ray images appears to be at an angle to the metacarpal shaft, it is often referred to as ***oblique***, ***transverse***, or ***spiral*** (see below):

Oblique Fracture

Transverse Fracture

Spiral Fracture

- **Closed fracture vs. open fracture**: When the soft tissue has been punctured or violated the fracture is considered open.

Open fractures can be classified further, with **Type I** being least damaging and **Type II** be most severe with more soft tissue damage.

All fractures with soft tissue damage should be assumed open until proven otherwise. Open fractures should be referred to a specialist or the emergency room as soon as possible. If there is going to be a delay of more than 3 hours, the wound should be irrigated and covered with betadine gauze. Antibiotics should be started.

3. Evaluation:

- Initial patient history should include hand dominance, age, occupation/job detail, and any additional co-morbidities. Illnesses such as diabetes, peripheral vascular disease, or other medical histories should also be noted.

- Displaced, angulated, or malrotated fractures should also be stabilized as soon as possible. The best opportunity for closed reduction of these fractures is within the first few hours following injury, since swelling can rapidly follow.

- Superficial lacerations are irrigated and sutured with loose approximation of the skin edges to allow for swelling. The wound is then dressed with an absorbent, non-constrictive dressing.

- Mechanism of injury, direction of any associated fall or force, and time/date of injury should be documented during the patient encounter. The provider should also screen the entire limb, noting any swelling, bruising, lacerations, and obvious deformities. Potential ***rotational deformities*** are best evaluated with fingers in flexion (see illustration at the top of previous page).

- Sensory evaluation including light touch sensitivity, sharp/dull, and any lack of feeling on the back or palm of hand/finger should also be documented.

4. Nonoperative Treatment (Closed Reduction):

Stable, non- or minimally-displaced fractures: A stable fracture is non- or minimally-displaced and in good functional position to heal. The broken ends of the bones meet up correctly and are aligned. In a stable fracture, the bones usually stay in place during the healing process.

An unstable fracture is already displaced or is likely to get displaced, rotated or shortened during the healing of the bone.

Transverse, shaft fractures can often be treated with cast or customized fracture bracing if referral to a therapist is an option (see picture below).

The recommended treatment timeline is as follows:

a. 0-3 WEEKS POST INJURY: Short arm cast or splint placed for 3 weeks, followed by a removable splint until there is radiographic evidence of healing.

Position of the hand while in the cast is crucial: *The hand should be in the "safe position." Three points of contact, one over the back/dorsal apex of the fracture, two within the palm-one distal, and one proximal to the fracture line will aid in minimizing shortening.*

Non-operative treatment uses MCP joint flexion to relax the hand muscles, and uses the collateral ligaments and force on the flexed proximal phalanx to reduce the fracture. Immobilization with at least 60 to 70 degrees of MCPJ flexion, with the fingers extended, limits stiffness. **Follow-up radiographs should be obtained weekly for 4 weeks and compared to the original film to prevent loss of reduction.**

b. 3-4 WEEKS POST INJURY (once there has been some healing):

- Begin AROM exercises to digit (out of removable splint for exercises only), 3-5 sessions per day.
- Emphasize importance of bending at 1st hand joint (MCP) and lifting finger off table with hand flat (to isolate finger extensor muscle).

c. 5-6 WEEKS POST INJURY:

- PROM to joints of finger/hand may begin.
- Focus on maximizing return of MCPJ flexion (fist) within first 6-8 weeks after injury.
- Use of splinting and/or buddy taping to encourage flexion may be considered.
- ***See examples of splints on the next page***.

Examples of Splints Used 5–6 Weeks Post Injury:

*The **clam digger or ulnar gutter splint** can be custom molded. Some prefer to use pre-fabricated styles.*

Hand-Based Metacarpal Fracture Brace (designed by J. Colditz, OTR/L, CHT)

This custom-molded splint/orthosis protects the healing 5th metacarpal fracture from external forces. The patient works actively to maintain proximal and distal inter-phalangeal joint motion while in the splint, and periodically removes it to gently, actively flex and extend the MCP joint.

d. 6-8 WEEKS POST INJURY:

- Progressive strengthening may begin.

5. Indications for Consultation to Orthopedic Services:

a. Multiple fractures
b. Oblique fractures
c. Spiral fractures
d. Open fractures
e. Comminuted fractures
f. Complex patients with low tolerance (e.g., post-head injury or frail elderly)
g. Displaced fractures > 1 mm.
h. Intra-articular fractures of any metacarpal.

It is crucial that the provider and health services staff understand any and all procedures that have been performed by orthopedic or other specialty services: to assure compliance with any specific post-procedure/post-operative precautions, and to provide re-education to patient to optimize patient compliance. (See **Caution/Warning** in box below.)

CAUTION/WARNING:

In most cases, patients who have had an injury or a surgical procedure on the hand or fingers should not be immobilized continuously (24/7) for more than 3-4 weeks; tendon repair may be the exception.

If no post-operative instructions were given, and the inmate is at least 4 weeks out from surgery or injury (if no surgery done), then a member of the primary care team should call the surgeon's office for specific instructions or clarification.

With limited exceptions, all metacarpal fractures managed operatively will be referred in BEMR to one of the two current Certified Hand Therapists in the BOP with notification to the respective Regional Medical Director. The goal of this process is to establish some oversight of these injuries (primarily by the hand therapists and the referring health provider) to ensure appropriate management and optimize outcomes.

6. Potential Operative and/or Invasive Treatments:

a. K-wire fixation or percutaneous pins:

b. Open reduction internal fixation (ORIF), utilizing screws, plates, and/or wires:

7. Clinical Pathway:

See attached algorithm for *Management of Metacarpal Fractures*.

Management of Proximal Interphalangeal Joint (PIPJ) Dislocations

Note 1- If injury includes radial collateral ligament of the index finger or the ulnar collateral ligament of the small finger, a finger gutter splint should be worn at all times in place of daytime buddy taping. This is because the tension placed on the healing structures from buddy taping can lead to gapping and/or and increased time to heal.

Note 2- Requested views on x-ray should include AP, Lat, Lat with the PIP joint in full flexion and Lat with the PIP joint in full extension. If the PIP joint does not stay reduced in either flexion or extension, splint the PIP joint in the stable position and refer to orthopedic specialist. The stable position for the PIP joint that is irreducible in flexion is full extension. Likewise, the stable position of the PIP joint that is irreducible in extension is splinted with the joint at least 30 degrees, but no more than 60 degrees short of full extension.

A true lateral radiograph with joint in full extension confirms post-reduction stability. If initial closed reduction of a dislocation without fracture is not successful, a complex dislocation is likely, requiring a referral to a specialist.

Note 3- Immediate, post-reduction x-ray after manipulation. If **NOT** reducible, ortho referral indicated. Follow-up x-ray recommended in 1 week if: a). manipulation was required; b.) intra-articular fracture was present; c.) extension block splinting required to maintain reduction; or d.) failing to progress with motion after 1 week.

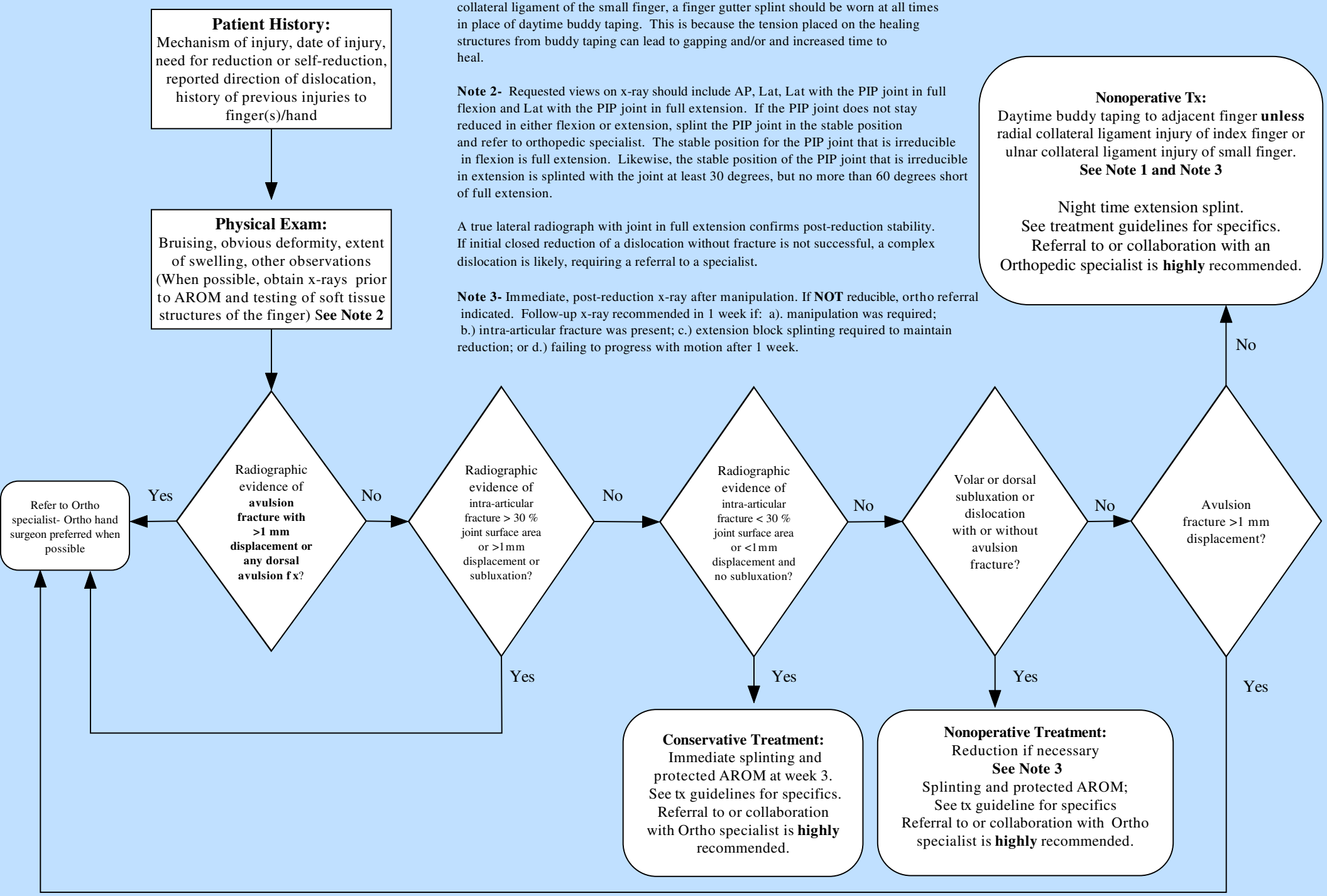

Federal Bureau of Prisons
Clinical Practice Guidelines

MANAGEMENT OF PROXIMAL INTERPHALANGEAL JOINT (PIPJ) DISLOCATIONS

December 2012

PURPOSE

The Federal Bureau of Prisons Clinical Practice Guidelines for Management of Proximal Interphalangeal Joint (PIPJ) Dislocations provide an overview regarding evaluation and appropriate treatments and/or referrals for PIP joint dislocations, including both volar and dorsal dislocations, and PIP joint dislocations with and without evidence of phalanx fracture.

This evidence-based protocol is designed as a guide so that the front-line clinician can manage acute hand injuries with the confidence inherent in standardized practice. A thorough examination and close, consistent follow-up care are essential for achieving satisfactory outcomes.

REFERENCES

Campbell PJ, Wilson RL. Management of joint injuries and intraarticular fractures. In: Mackin EJ, Callahan AD, Skirven TM, et al, eds. *Rehabilitation of the Hand: Surgery and Therapy,* Vol 1. 5th ed. St. Louis, MO: Mosby; 2002:396-411.

Chinchalkar SJ, Gan BS. Management of proximal interphalangeal joint fractures and dislocations. *J Hand Ther*. 2003;16(2):117-128.

Koczan BJ, Moore S. Ligament injuries of the hand. In: Burke SL, Higgins JP, McClinton MA, Saunder RJ, Valdata L, eds. *Hand and Upper Extremity Rehabilitation: A Practical Guide.* St. Louis, MO; Elsevier; 1993:547-560.

LaStayo PC, Winters KM, Hardy M. Fracture healing: bone healing, fracture management, and current concepts related to the hand. *J Hand Ther* [serial online]. 2003;16(2):81-93. Accessed February 12, 2011.

DEFINITIONS

- ***Proximal interphalangeal phalanx (PIP) joint:***
  A hinge joint, allowing for flexion/extension of digits with an arc of 100 degrees motion. The PIP joint is one of the most unforgiving joints in the body when it comes to injury. What at first appears to be a simple sprain of this joint may result in a painful and stiff finger, making it difficult to use the hand for gripping activities.

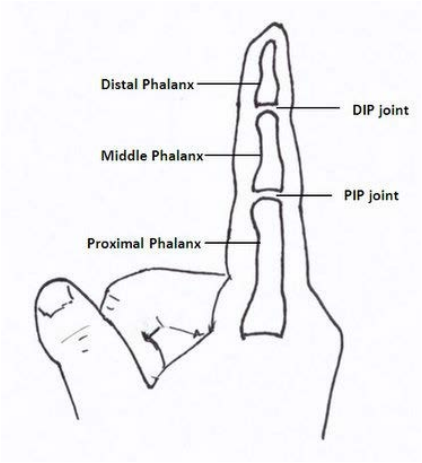

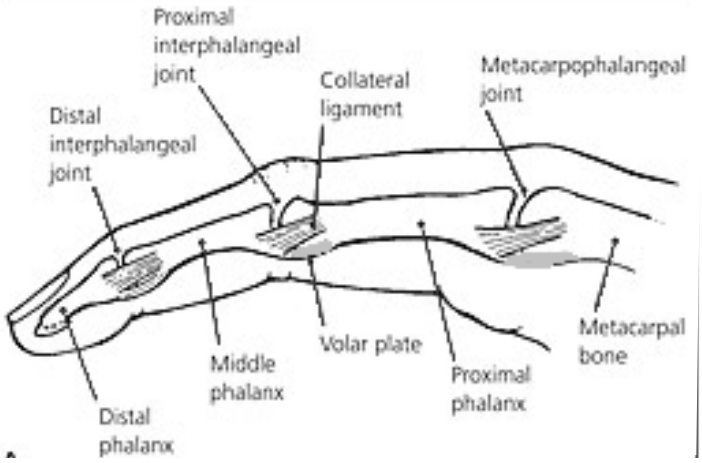

Note: *For a more detailed illustration of the PIP joint, see* ***Figure 6*** *under "Procedures.")*

- ***Buddy splinting/taping:***
  Taping or splint that pairs the injured finger to an adjacent non-injured finger to provide stability, while facilitating movement of the injured finger.

Figure 1a

Figure 1b

- ***Dorsal dislocation of PIP joint***
  The middle phalanx moves dorsally in relation to proximal phalanx. Hyperextension of a finger joint, such as a dorsal dislocation, can injure the volar plate (see discussion of ***volar plate*** on next page).

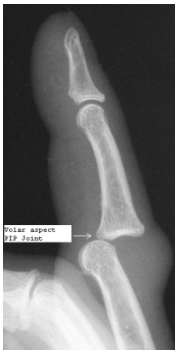

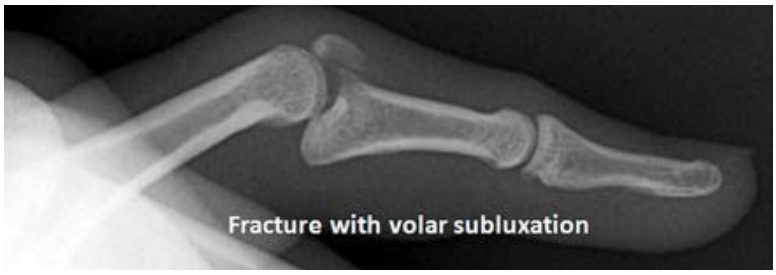

Dorsal dislocation

- ***Extension block splint:***
  A common technique for both primary treatment of reduced dorsal dislocations/fracture-dislocations at the PIP joint, and as a rehabilitation method following reduction of such injuries. This treatment method is a classic example of two orthopedic principles: (1) stable arc splinting and (2) early protected motion. **Figure 2** shows the affected PIP joint immobilized in 45 degrees of flexion. **Figures 3 and 4** show the patient maintaining blocked extension of the PIP joint, while full available active flexion is encouraged frequently within the stable arc of motion.

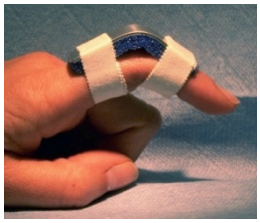

Figure 2

Figure 3

Figure 4

- ***Finger gutter splint:***
  A finger extension splint designed to provide stable immobilization for fractures, dislocations, and ligamentous and fingertip injuries.

Sammons Rolyan Finger Gutter Splint Kit by SAMMONS PRESTON

Figure 5

- ***Joint laxity:***
  The degree of looseness at a particular joint. Joint laxity can mean that a joint is less stable, which can lead to excessive motion and pain.

- ***Volar plate:***
  Forms volar/palmar support of PIP joint; ligamentous at origin of the proximal phalanx and becomes more cartilaginous as it inserts into middle phalanx. The volar plate is the main component in preventing hyperextension of the PIP joint. The volar plate can be partially or completely torn, with or without an avulsion fracture. If the fracture fragment is large and involves a significant amount of the joint surface, it may require surgery to fix the fragment and restore the joint surface.

  An avulsion fracture involving more than one third of the joint, or a joint that is irreducible, will require referral to an orthopedic specialist. A positive sign for volar plate disruption will be hyperextension at the PIP joint.

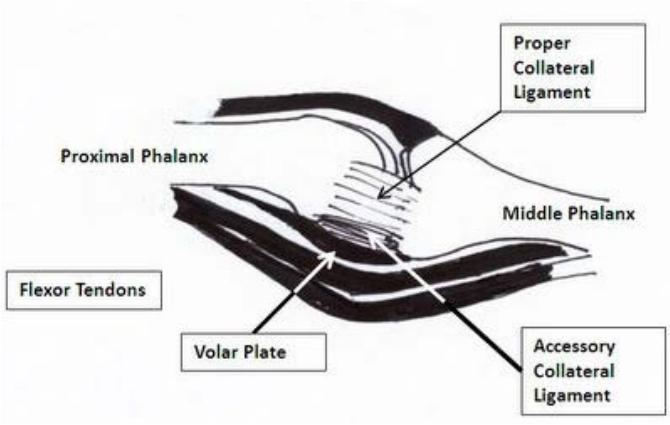

X-ray of normal middle finger

- ***Volar dislocation of PIP joint:***
  Middle phalanx moves volar in relation to proximal phalanx.

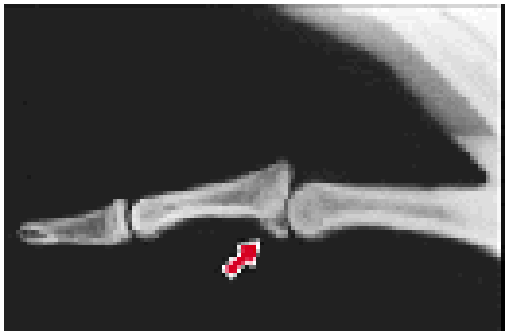

Volar plate avulsion fracture with dorsal subluxation

PROCEDURES

1. Introduction:

- An evaluation to gather important information (including mechanism of injury, observed deformity at time of injury, time elapsed since injury, and previous injuries and treatments to the affected finger) is essential. Other areas to include in the evaluation are location and extent of any swelling, ecchymosis (bruising), and specific areas of tenderness around the PIP joint.
- **Ideally, radiographs are performed *prior to* evaluating joint stability and functional range of motion (ROM) to rule out any serious fractures.** If no evidence of fracture is present, the examiner should compare the radial and ulnar collateral ligament (RCL/UCL) stability/laxity with the patient's opposite hand/PIP joint.
- See ***Section 3***, ***Indications for Non-Operative Management of PIP Joint Injuries*** and ***Section 6***, ***Indications for Consultation to Orthopedic Services***.
- **Stability of the PIP joint is obtained in large part due to several ligaments surrounding the PIP joint.** These include the proper and accessory collateral ligaments (**PCL** and **ACL**), the volar plate (**VP**), and the dorsal capsule, which contains the extensor central slip (**ECS**).

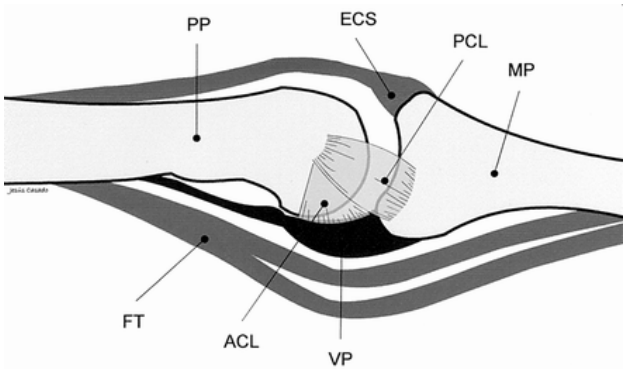

Figure 6, Anatomy of the PIP joint: Lateral view showing the accessory collateral ligament (ACL), extensor central slip (ECS), flexor tendons (FT), middle phalanx (MP), proper collateral ligament (PCL), proximal phalanx (PP), and volar plate (VP).

- Forced ulnar or radial deviation at any of the interphalangeal joints can cause partial or complete collateral ligament tears. The PIP joint usually is involved in collateral ligament injuries, which are commonly diagnosed as "jammed fingers."

2. Treatment Pitfalls:

When treating a finger injury non-operatively, avoid the following pitfalls:

- Attempting to treat an unstable joint with a splint, without confirming that the joint is reduced in the splint.
- **Joint stiffness caused by inappropriate splinting**: Inappropriate splinting in this case is defined as a splint that is applied for too long a time period, without sound clinical reasoning or using an ill-advised splint. For example, use of a rigid splint is not advised if buddy taping is sufficient. Likewise, immobilizing the entire finger is not indicated if immobilizing the PIP joint is sufficient.
- **Inadequate early follow-up, resulting in loss of reduction and/or malunion:**
  - Radiographs and close follow-up are required in the early-healing phase.
  - Weekly follow-up for the first 3 weeks is usually sufficient, followed by follow-up every 3-4 weeks until full function of the affected finger is restored or the patient requires a referral to an orthopedic specialist.

WARNING/CAUTION:

A small, volar plate avulsion fragment is often present after PIP joint injuries. In most cases, these injuries will heal with scar tissue instead of bone. Mechanically, the joint is usually stable; however, these patients must be informed that while the bone fragment is not likely to show healing on x-ray, it is seldom, if ever, the cause of persistent pain.

Some persistent swelling and stiffness is likely for as long as 6 months or more after injury. Most patients will not reach maximal improvement for at least a year, and the joint will always be larger than it was before the injury.

Overtreating these injuries with prolonged splinting may lead to a stiff joint.

3. Indications for Non-Operative Management of PIP Joint Injuries:

- It is essential to obtain radiological study of the involved finger(s). Requested views should include AP, Lat, Lat with the PIP joint in maximal flexion, and Lat with the PIP joint in maximal extension.
- **If the PIP joint does not stay reduced in either flexion or extension, splint the PIP joint in the STABLE POSITION and refer to an orthopedic specialist.**
  - The **STABLE POSITION** for the PIP joint that is irreducible in flexion is full extension (**Figure 7**).
  - The **STABLE POSITION** of the PIP joint that is irreducible in extension is splinted with the joint at least 30 degrees, but no more than 60 degrees, short of full extension (**Figure 8**).

Figure 7

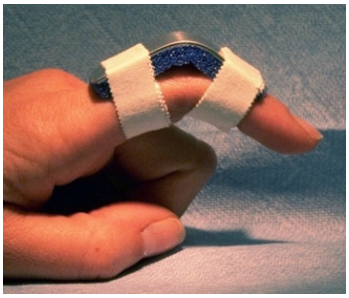

Figure 8

- A true lateral radiograph with the joint in maximal extension confirms post-reduction stability. **If initial closed reduction of a dislocation without a fracture is not successful, a complex dislocation is likely to be present, requiring a referral to a specialist.**
- **It is important to check for subtle signs of instability on post-reduction lateral radiographs of the digit.** A true lateral radiograph should show a congruent joint space with two parallel surfaces. Divergence of the posterior articular surfaces from the central portion of the joint (a "V" sign) indicates incomplete reduction.

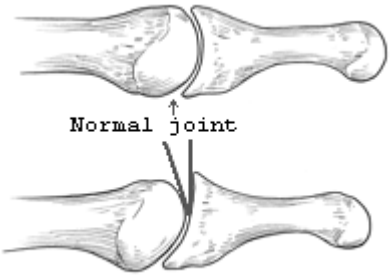

V sign showing sublux

4. Treatment: Incomplete UCL/RCL Tears with/without Nondisplaced Avulsion Fractures of Proximal or Middle Phalanx

Note: Referral to and/or collaboration with a specialist is optional.

- **WEEKS 0–3:** Use daytime buddy taping (see **Figures 1a and 1b**) involving digit-to-adjacent-digit on the same side as the injury.

  RCL injuries of index finger and UCL injuries of the small finger should be splinted in an extension gutter splint (see Figure 5), with gentle AROM out of splint 3 times/day.

  Nighttime treatment includes use of an extension gutter splint, which may be used at all times for several days after injury if needed to control pain; however, gentle AROM with buddy taping should begin as soon as the patient can tolerate it.

  Weekly follow-up should occur to ensure patient compliance and that more serious problems are not overlooked, such as malunion, loss of reduction, or the development of a PIP joint flexion contracture.

- **WEEKS 3-6:** Continue extension splint at night as pain diminishes, and continue buddy splinting/taping during the day.

- **WEEKS 6-8:** Discontinue buddy taping and extension splint; begin progressive strengthening. Unrestricted use can begin by week 8.

- **It is highly recommended that the patient continue to buddy tape the affected finger for up to one year after injury when participating in sports or activities where the risk of re-injury is great, e.g., football, basketball, handball, soccer.**

WARNING/CAUTION:

It is imperative to maintain joint reduction. This is the primary goal of treatment and may dictate post-injury management, such as limiting early mobilization of the affected finger.

5. **<u>Treatment</u>: Intra-articular Fracture and Volar or Dorsal Dislocation/Subluxation of PIPJ with Stable, Closed Reduction**

a. **<u>Stable, closed reduction</u>: Volar-based fragment (radiographic evidence of intra-articular fracture < 30% of joint surface area or < 1mm displacement).**

- **WEEKS 1-3:** Utilize extension block splint to reduce volar-based fragment (alumifoam or hand-based thermoplastic splint; see **Figure 9** below).

  The extension block splint should place the PIP joint in at **least 30 degrees of flexion, but no more than 60 degrees** of flexion for two weeks. X-rays should be used to confirm reduction in the splint.

  In the unstable joint, dorsal dislocation normally occurs at less than full extension, and is usually treated with an extension block splint set at 20 to 30 degrees less extension from the point of being stable.

- **At WEEK 3:** The extension block splint is increased 10 degrees. A lateral x-ray should be obtained to confirm that the joint stays reduced each time the splint is adjusted. Buddy splinting is initiated to facilitate AROM into flexion to include the PIP and DIP joints.

  This combination of buddy taping and extension block splinting is utilized to encourage early active-assistive range of motion (AAROM) while preventing joint subluxation (see **Figures 9** and **10** below).

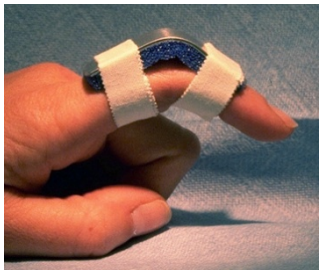

Figure 9

Figure 10

The allowed range of motion is increased to full extension over 3 to 8 weeks, depending on the stability of the joint. The affected finger is kept taped to splint nearly fulltime until week 5 (Fig. 9). However, the tape nearest the tip of the finger is removed 10-12 times daily, allowing the PIPJ and DIPJ to actively flex within the splint 20-25 times for each session (Fig. 10).

- **At WEEK 4:** The extension block splint is increased 10 more degrees.

- **At WEEK 5:** The extension block splint is increased 10 more degrees. Begin to wean out of extension blocking splint.

- **At WEEK 6:** Passive Range of Motion (PROM) exercises are initiated.
- **WEEKS 8-10:** Begin resistive exercises. It is highly recommended that the patient continue to buddy tape the affected finger for up to one year after injury when participating in sports or activities where the risk of re-injury is great, e.g., football, basketball, handball, soccer.

b. Stable, closed reduction: Volar-based fragment (radiographic evidence of intra-articular fracture > 30% of joint surface area or > 1mm displacement).

Splinting and referral to an orthopedic surgeon within one week of injury is recommended. However, if there is a delay, treatment should proceed as follows until the patient can be seen:

- Immobilize with PIP joint in extension.
- If the inmate cannot be seen by a consultant by 3 weeks post-injury, then proceed with the recommendations under 5.a. above (volar-based fragment, where the fracture is < 30% of joint surface area or has < 1mm displacement).

c. Stable, closed reduction: Dorsal-based fragment

Splinting and referral to an orthopedic surgeon within one week of injury is recommended. However, if there is a delay, treatment should proceed as follows until the patient can be seen:

- **WEEKS 1-3:** Three weeks immobilization in extension 24 hours a day/7 days a week for involved PIP joint using alumifoam material (see **Figure 7**).
  - **AROM to noninvolved joints and DIP joint of injured finger** is essential to prevent ligament and joint tightness (see **Figures 11a** and **11b** below).

Figure 11a

Figure 11b

- **Weekly follow-up** should occur to ensure patient compliance and that more serious problems are not overlooked, such as malunion or loss of reduction.

- **WEEKS 3-4:** Initiate AROM to the involved joint 6-8 times daily; splint is worn in between exercises and at night.

  Monitor PIPJ for development of extension lag; if lag appears, re-initiate immobilization of PIP joint 24/7 for 3 more weeks.

- **WEEKS 4-6:** If extension lag does not appear, initiate PROM and wean from splint; use splinting to regain extension/flexion deficits as indicated; continue AROM.

  If extension lag was apparent at weeks 3-4 and full-time immobilization was re-initiated, restart protocol beginning at parameters for weeks 3-4 and closely monitor for development of extension lag. If lag reappears, refer patient to a specialist.

- **WEEKS 8-10:** Initiate resistive exercises. It is highly recommended that the patient continue to buddy tape the affected finger for up to one year after injury when participating in sports or activities where the risk of re-injury is great, e.g., football, basketball, handball, soccer.

6. Indications for Consultation to Orthopedic Services:

a. Complete UCL/RCL tears.

b. Fractures involving more than 30% of the joint surface, which tend to be unstable.

c. Displaced avulsion fractures at the site of UCL/RCL attachment.

d. Complete UCL/RCL tears with combined volar plate rupture.

e. Unstable/unable to maintain reduction with gentle, protected AROM.

f. Compound or other significant proximal or middle phalanx fractures.

g. Development of extension lag at the PIP joint when AROM is initiated, after full or nearly full extension had been achieved.

7. Clinical Pathway:

See attached algorithm for *Management of Proximal Interphalangeal Joint (PIPJ) Dislocations*.

Management of Scaphoid Fractures

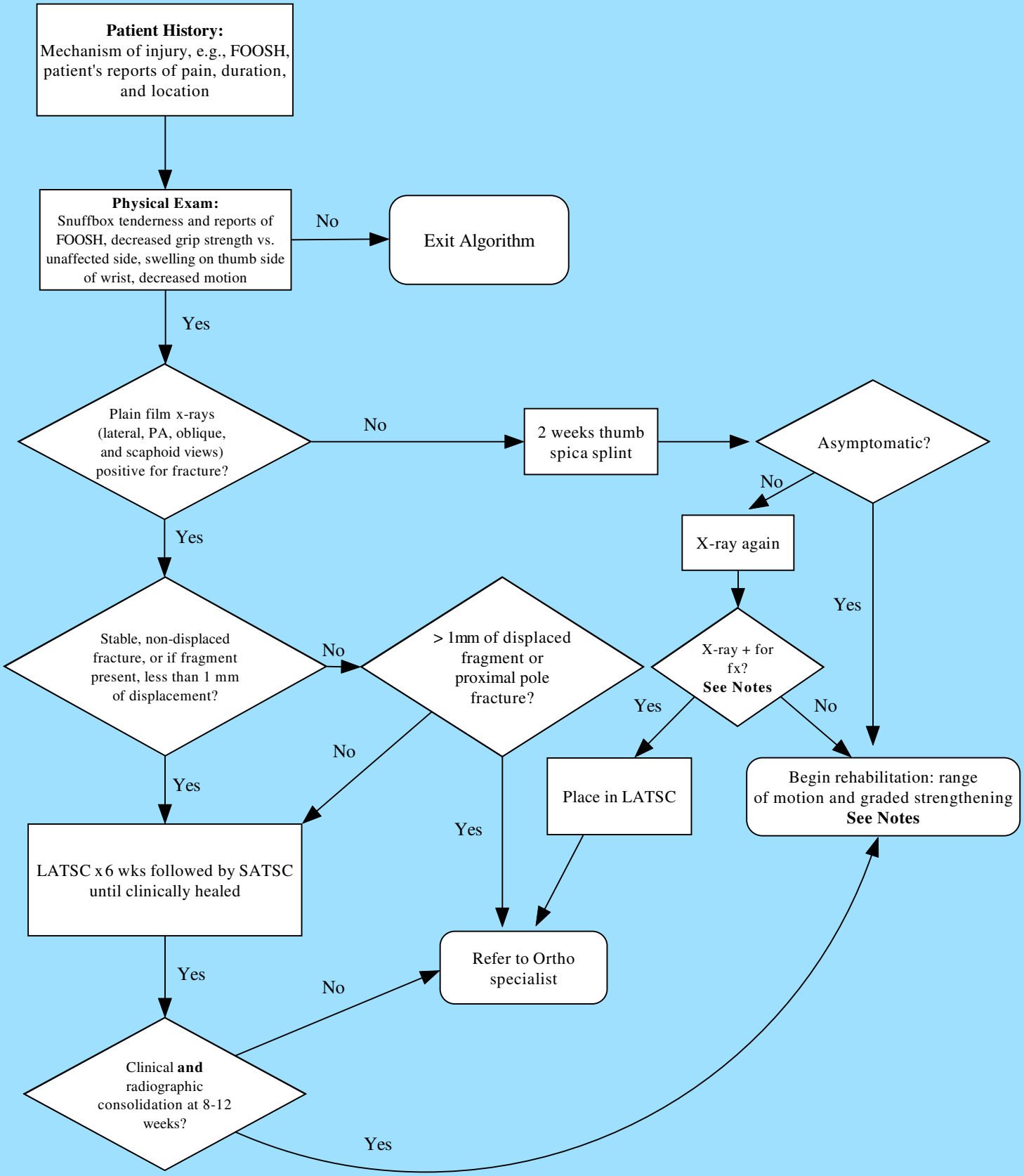

Note 1- If the second x-ray at the 2-week period is negative, yet the patient continues to be symptomatic, an MRI is then warranted. The MRI **can be** done with cast on patient. The MRI result may be negative for scaphoid fracture, yet positive for other soft tissue injury, for which a referral to a specialist is still indicated.

Note 2- If a patient requires that a cast be applied, **it is highly recommended that the patient be followed** up 1-3 days after the cast is initially applied, and then again 10-14 days later, with 4-week follow-ups thereafter. This is to ensure that the patient's neurovascular status has not been compromised, and that the cast is providing adequate stabilization/reduction of the fracture.

Federal Bureau of Prisons
Clinical Practice Guidelines

MANAGEMENT OF SCAPHOID FRACTURES

December 2012

PURPOSE

The Federal Bureau of Prisons Clinical Practice Guidelines for the Management of Scaphoid Fractures provide evidenced-based recommendations or guidelines for the outpatient management of federal inmates with acute scaphoid fractures.

This evidence-based protocol is designed as a guide so that the front-line clinician can manage acute hand injuries with the confidence inherent in standardized practice. A thorough examination and close, consistent follow-up care are essential for achieving satisfactory outcomes.

REFERENCES

Cooney WP, Dobyns JH, Linscheid RL. Fractures of the scaphoid: a rational approach to management. *Clin Othop Relat Res.* 1980; (149):90-97.

Dell PC, Dell RB. Management of carpal fractures and dislocations. In: Mackin EJ, Callahan AD, Skirven TM, et al, eds. *Rehabilitation of the Hand: Surgery and Therapy. Vol 1*. 5th ed. St. Louis, MI: Mosby; 2002:1171-1173.

Grover R. Clinical Assessment of scaphoid injuries and the detection of fractures. *J Hand Surg Br.* 1996;21(3):341-343.

Pillai A, Jain M. Management of clinical fractures of the scaphoid: results of an audit and literature review. *Eur J Emerg Med*. 2005; 12(2):47-51.

DEFINITIONS

- ***Scaphoid:***
  Peanut-shaped bone on the thumb side of the wrist. Some providers refer to this bone as the "navicular."

- ***Anatomical snuffbox:***
  A hollow seen on the thumb-side aspect of the back of the wrist when the thumb is extended fully.

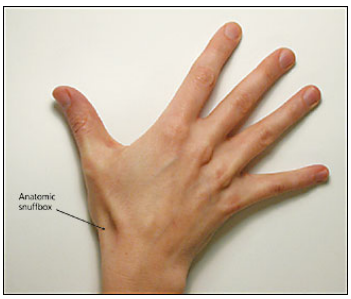

Figure 1

- ***Avascular necrosis (AVN):***
  Death of bone components due to interrupted blood supply.

- ***Fall on outstretched hand (FOOSH):***
  A fall that results in a person landing on the palm of the hand, forcing the wrist into hyperextension.

- ***Long arm thumb spica cast (LATSC):***
  A cast applied from the upper arm to the hand to include the thumb, but excluding the distal joint. (*Compare to* ***SATSC*** *below*.)

Figure 2

- ***Proximal pole fracture:***
  Fractures of the scaphoid are localized within the proximal, middle (waist), or distal third of the bone. The incidence of avascular necrosis increases with fractures that are located more proximally in poorly vascularized areas.

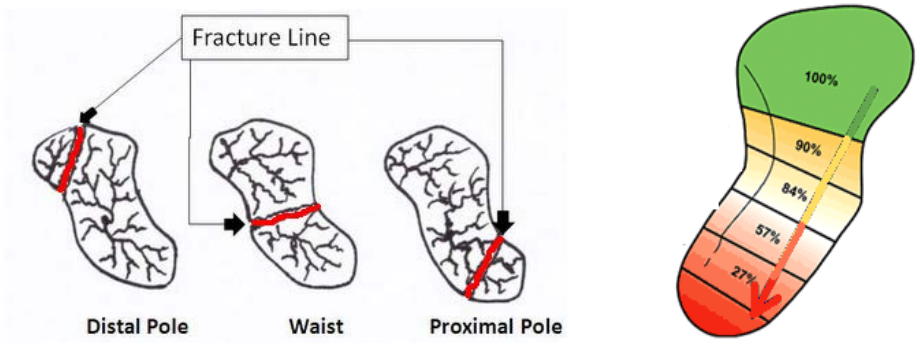

Figure 3: Healing Rate by Location of Fracture

- ***Scaphoid view:***
  X-ray of the wrist in ulnar deviation so that the entire profile of the scaphoid can be seen.

- ***Short arm thumb spica cast (SATSC):***
  A cast applied from the upper forearm to the hand to include the thumb. (*Compare to* ***LATSC*** *above*.)

Figure 4

- ***Thumb spica splint:***
  A splint applied from the upper forearm to the hand to include the thumb.

Figure 5

PROCEDURES

1. Introduction:

The diagnosis of “wrist sprain” continues to be a common diagnosis for the patient who has experienced a wrist injury. However, misdiagnosis or failure to identify a wrist fracture, specifically a scaphoid fracture, may lead to: delayed healing requiring surgical management, increased cost to treat, and subsequent long-term loss of function of the affected hand.

Scaphoid fractures account for about 60 percent of wrist (carpal) fractures. The mechanism of injury for a scaphoid fracture is typically a FOOSH where the wrist is hyperextended and combined with radial deviation of the wrist. It is a common injury in sports.

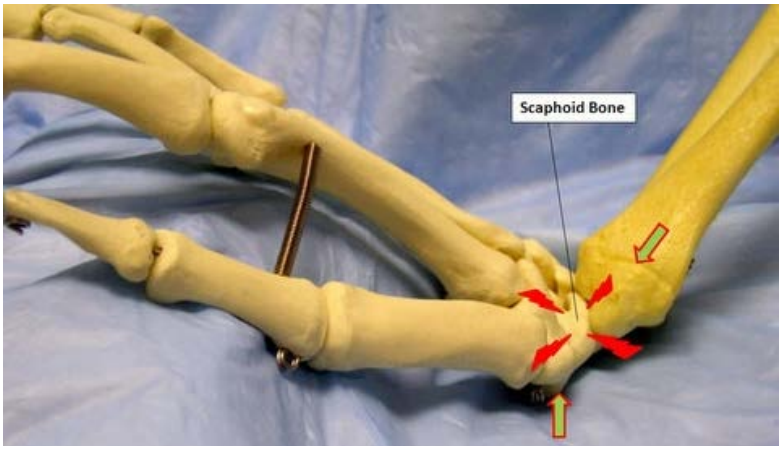

The angle at which the hand hits the ground typically determines the injury. As a general rule, if the wrist is bent backward at a 90-degree angle or more, the scaphoid will break; if the angle of wrist extension is less than 90 degrees, the lower arm bone or radius will break. Because the scaphoid is poorly vascularized, it is notoriously slow to heal, which makes early identification and treatment even more important given that avascular necrosis is a common concern.

2. Evaluation:

- **Of all the wrist injuries, fracture of the scaphoid is the most commonly missed diagnosis.** It is not out of the ordinary for this injury to be associated with other injuries of the upper extremity, and the wrist may be a lower priority from the patient’s perspective. Also, a significant percentage of these fractures will not be visible on x-ray with any view, especially if the injury was very recent.

- **The diagnosis of scaphoid fracture** is based on a history of trauma to the wrist (usually a fall or accident), a clinical exam that shows tenderness in the snuffbox region (**Figure 1**) of the affected wrist, and x-rays that may or may not show a fracture.
- **Signs and symptoms of a scaphoid fracture** include pain and tenderness on the thumb side of the wrist. Motion and gripping with the affected hand may be painful. Decreased grip strength when compared to the other hand will likely exist. Limited motion and pain at the end range of motion, especially flexion and radial deviation, may exist. There may also be swelling on the back and thumb side of wrist. Pain may subside and then return as a deep, dull aching.
- Because early x-rays appear normal for many patients, diagnosing a scaphoid fracture can be challenging. **With a supportive history and clinical exam, the diagnosis of scaphoid fracture should be assumed until proven otherwise. Palpation of the snuffbox is the most reliable diagnostic test for acute scaphoid fracture.**

3. Indications for Non-Operative Management of Scaphoid Fractures:

All patients with wrist injuries involving a FOOSH and with marked snuffbox tenderness should be treated as having a scaphoid fracture, regardless if radiographs are negative. Strict adherence to this policy will ensure that any fracture with subtle or absent radiographic initial findings will still be appropriately treated without delay.

- Plain-film x-rays should be obtained as soon as it is reasonable. X-rays include lateral, posteroanterior (PA), and scaphoid views.
- If there will be a delay in getting the x-rays, a thumb spica splint (**Figure 5**) should be applied and then removed when x-rays can be obtained.
- If x-rays are initially negative, but suspicion remains high for a scaphoid fracture, a thumb spica splint is applied. This splint is worn for 10-14 days and then removed.
- A clinical exam is again performed, as well as new radiographs obtained. If clinical findings are consistent with a scaphoid injury, yet the x-ray is negative, a long arm thumb spica cast (LATSC) is applied and an MRI is indicated.

  A LATSC includes the thumb and places the elbow in 90 degrees of flexion, the forearm in neutral (thumb up), the wrist slightly flexed and radially-deviated, and the thumb extended (see **Figure 2**). **The patient should be followed up 24-48 hours**

after the cast is applied to check neurovascular status, and then again 7-10 days after the cast was applied.

- An MRI is considered to be the gold standard for detecting a scaphoid fracture, with a sensitivity of 95–100% and specificity near 100%. The benefit of an MRI, as opposed to a bone scan, includes the ability to identify and diagnose other causes of wrist pain if a scaphoid fracture is not present.

4. Treatment of Stable, Non-Displaced Scaphoid Fractures:

- LATSC for 6 weeks, followed by a short arm thumb spica cast (SATSC) (**Figure 4**) until clinical and radiographic signs of union are seen.

- **For the first 6 weeks,** consider changing the cast every 3 weeks so that it remains firm around forearm muscles and the wrist. X-rays are obtained out of the cast at each cast change.

- **After the first 6 weeks**, the cast is removed every 4 weeks to ensure healing is occurring. X-rays are obtained out the cast at each cast change until there is radiographic evidence of healing.

- **Immobilization for 16 weeks to 6 months is sometimes required.** Healing time is normally longer for fractures in the lower part of the scaphoid (toward the wrist) and shorter for fractures in the middle of the scaphoid and at the top portion of the bone (see **Figure 3**). Average healing times by the position of the fracture are as follows:
  - **Distal third fractures (top of bone):** approximately 6-8 weeks
  - **Middle portion:** approximately 8-12 weeks
  - **Proximal third (bottom of bone):** 12-24 weeks

- **If radiographic evidence of healing is noted, casting can be discontinued, BUT a wrist cockup splint should be worn in place of the cast.** In the prison environment, the splint should be worn for 3 months after cast removal while on the compound and while sleeping. The splint should be continued for at least 6 months if the inmate is participating in sports activities. The splint should be removed daily for bathing and for the inmate to do range of motion exercises.

- Initiate a rehabilitation program consisting of motion and strengthening once healing has taken place.

5. Indications for Consultation by Orthopedic Services, preferably Orthopedic Hand Surgeon when available:

a. Non-united fractures after 6 months of conservative treatment.

b. Displaced fractures by 1 mm or more.

c. Scaphoid fractures accompanied by other injuries such as a distal radius fracture.

d. Comminuted fractures.

e. Fractures through the proximal pole of the scaphoid.

6. Clinical Pathway:

See attached algorithm for *Management of Scaphoid Fractures*.

Management of Chronic Shoulder Pain

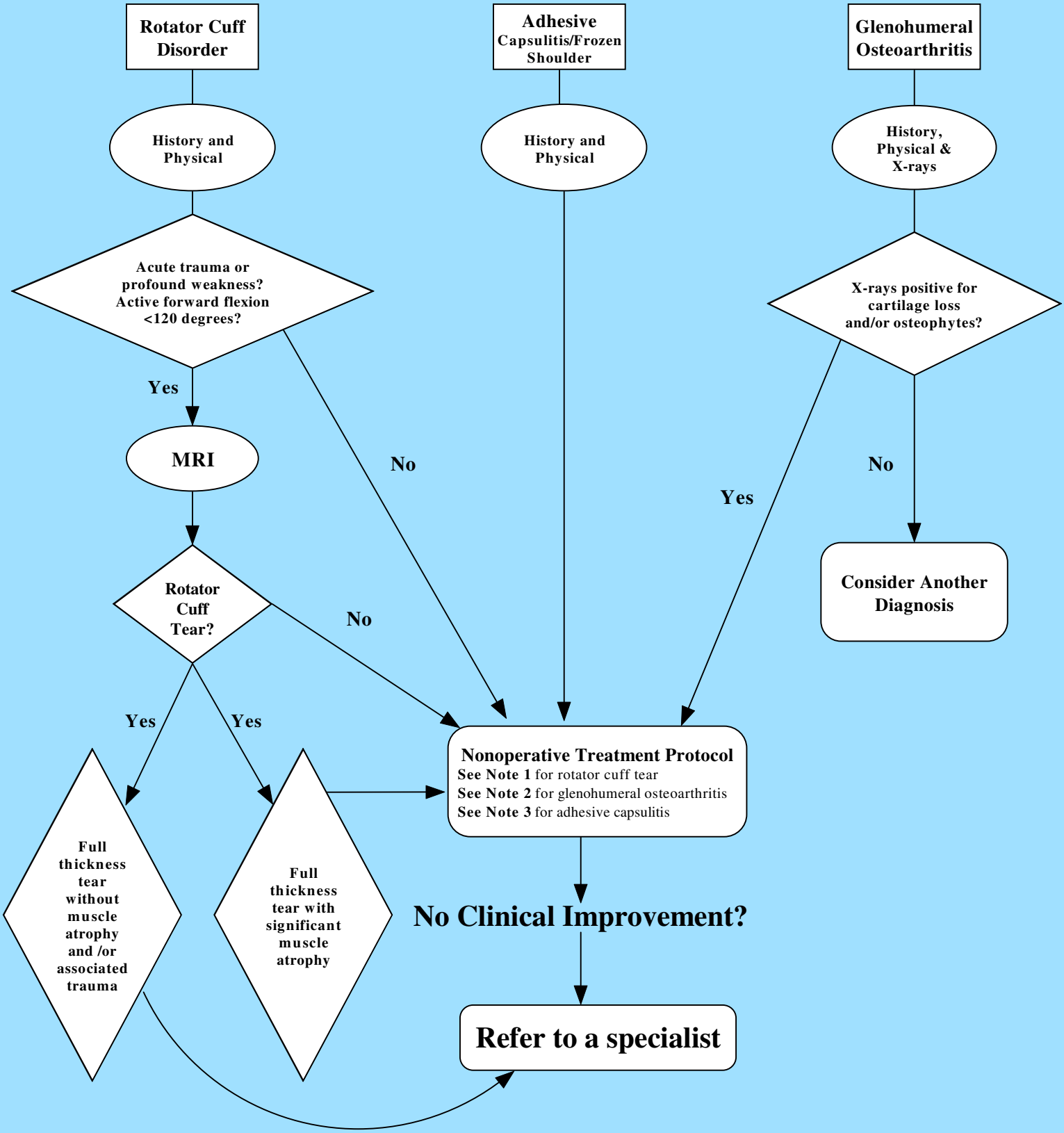

Note 1 Rotator cuff tear- nonoperative treatment protocol should be pursued for a minimum of three to six months without improvement before referral to specialist is initiated.

Note 2 Glenohumeral osteoarthritis- loss of function (i.e., unable to lift hand to opposite shoulder, behind head, or behind back to tuck in shirt) and/or pain not controlled with activity modification, therapy, and pharmacologic strategies justify a referral to a specialist.

Note 3 Adhesive capsulitis- nonoperative treatment protocol for up to 12 months should be initial approach for this diagnosis.

Nonoperative Treatment Protocol-
Chronic Shoulder Pain

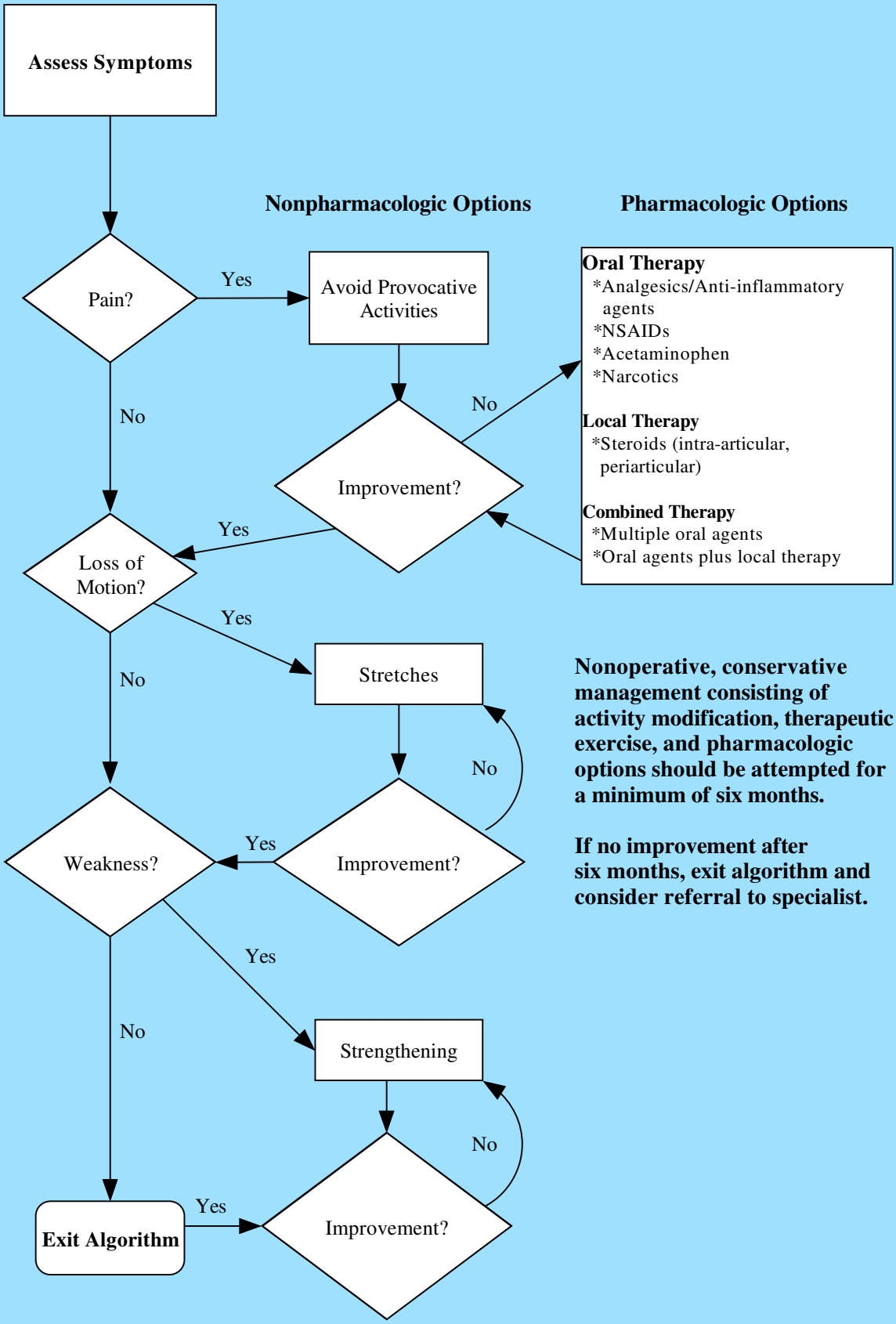

Nonoperative, conservative management consisting of activity modification, therapeutic exercise, and pharmacologic options should be attempted for a minimum of six months.

If no improvement after six months, exit algorithm and consider referral to specialist.

Federal Bureau of Prisons
Clinical Practice Guidelines

MANAGEMENT OF CHRONIC SHOULDER PAIN

December 2012

PURPOSE

The Federal Bureau of Prisons Clinical Practice Guidelines for Management of Chronic Shoulder Pain provide evidenced-based recommendations or guidelines for the outpatient management of federal inmates with chronic, persistent shoulder pain.

This evidence-based protocol is designed as a guide so that the front-line clinician can manage shoulder conditions with the confidence inherent in standardized practice. A thorough examination and close, consistent follow-up care are essential for achieving satisfactory outcomes.

REFERENCES

American Academy of Orthopaedic Surgeons, *AAOS Clinical Guideline on Shoulder Pain Support*. Rosemont, IL: American Academy of Orthopaedic Surgeons; 2001.

Chase JM, Frieman BG, Fenlin, JM. Diagnosis and management of common shoulder problems. In: Mackin EJ, Callahan AD, Skirven TM, et al, eds. *Rehabilitation of the Hand: Surgery and Therapy, Vol 1*. 5th ed. St. Louis, MI: Mosby;2002:1171-1173.

Iannotti JP, Kwon, YW. Management of persistent shoulder pain: a treatment algorithm. *Am J of Ortho.* 2005;34(12):16-23.

Neer CS. Impingement lesions. *Clin Orthop.* 1983;173:70-77.

Steinfeld R, Valente RM, Stuart MJ. A common sense approach to shoulder problems. *Mayo Clin Proc.* 1999;74(8):785-794.

Uhthoff HK, Sarkar K. An algorithm for shoulder pain caused by soft tissue disorders. *Clin Ortho.p* 1990;254:121-127.

DEFINITIONS

- ***Acute injury phase:***

  For the purpose of this clinical pathway, the acute phase is defined as beginning at the time of injury up until 3-4 weeks from the injury.

- ***Adhesive capsulitis, "frozen shoulder":***

  A condition where the capsule surrounding the shoulder joint becomes inflamed and then contracted as scar tissue forms, creating a stiff, painful shoulder that is very limited in movement. The cause of adhesive capsulitis is not clear. Often is atraumatic in onset and commonly occurs in patients with diabetes.

- ***Glenohumeral instability:***

  Glenohumeral instability refers to symptomatic subluxation or dislocation of the humeral head in relation to the glenoid fossa. Intial treatment is rehabilitation, followed by surgery if indicated.

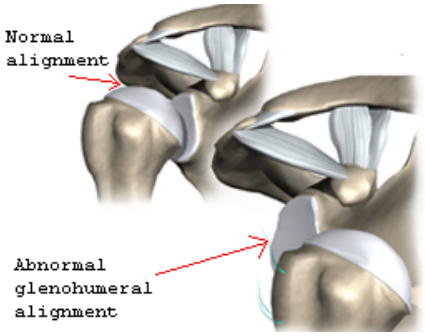

- ***Shoulder impingement syndrome:***

  A common shoulder condition seen in aging adults, overhead throwers, and individuals engaging in overly aggressive upper body workout routines. The rotator cuff muscles of the shoulder are sandwiched between the top of the arm bone (humerus) and the top of the shoulder (acromion). This unique arrangement of muscle between bone leads to the condition of impingement syndrome (shoulder bursitis, rotator cuff tendinitis).

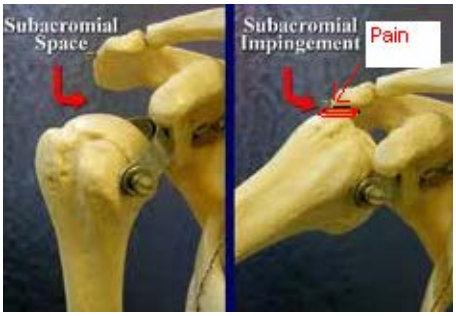

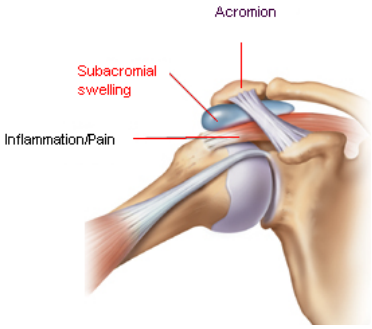

- ***Rotator cuff disorder:***

  The rotator cuff is a group of tough, flexible fibers (tendons), and muscles (supraspinatus, infraspinatus, teres minor, and subscapularis) in the shoulder. Rotator cuff disorders occur when tissues in the shoulder get irritated or damaged. Rotator cuff disorders include:

  - Inflammation of the tendons (tendinitis) or bursa (bursitis).
  - Impingement, in which a tendon is squeezed and rubs against bone.
  - Calcium buildup in the tendons, which causes a painful condition called calcific tendinitis.
  - Partial or complete tears of the rotator cuff muscles.

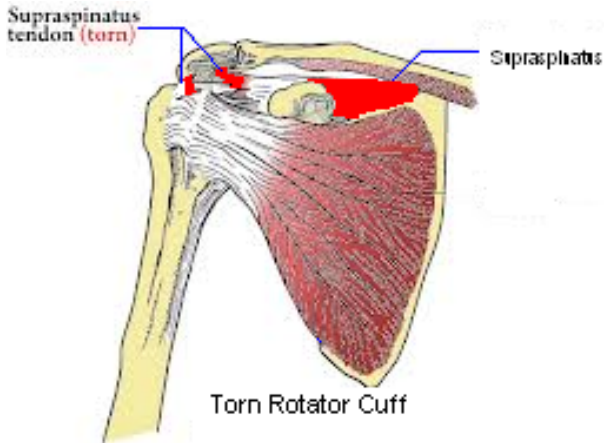

PROCEDURES

1. Introduction:

Shoulder pain is the third most-common musculoskeletal complaint in the general population, second only to knee pain for referrals to an orthopedic specialist. **Shoulder pain is defined as chronic when it has been present for longer than six months and can be divided into five general categories:**

(1) Rotator cuff disorders
(2) Adhesive capsulitis
(3) Glenohumeral osteoarthritis
(4) Glenohumeral instability
(5) Other chronic pains and non-shoulder problems

The challenge for the provider in evaluating shoulder pain is the potential for there being more than one cause, or the presence of multiple disorders. Causes can include jobs that require repetitive reaching above shoulder level or reaching away from the body. In addition, certain workout regimens by inmates in the BOP can also delay or prevent recovery, e.g., push-ups, bench pressing, triceps presses or dips, pull-ups, handball, overhead throwing activities, and burpees. It is essential that the inmate stop these aggravating activities during treatment

2. Patient's Age as a Consideration:

Table 1 demonstrates that the age of the patient is an important consideration when determining a diagnosis. Shoulder pain patients younger than 30 years old tend to have mild inflammatory conditions such as atraumatic instability and tendinitis. Less than 1% of shoulder injuries in people younger than 30 years old are complete rotator cuff tears.

Table 1: Differential Diagnosis of Shoulder Pain

Diagnosis	***Primary Care Setting (%)***	***Age (y) of presentation, Mean (SD)***
Shoulder Impingement Syndrome	48-72	
Stage I Tendinitis	16	23 (7)
Stage II Partial Tear	42	41 (11)
Stage III Full Thickness Tear	15	62 (12)
Adhesive Capsulitis	16-22	53 (10)
Acute Bursitis	17	
Calcific Tendonitis	6	
Glenohumeral Joint Arthritis	2.5	64 (10)

3. History Findings for Patients with Chronic Shoulder Pain:

Table 2 summarizes the history and associated shoulder conditions for patients with chronic shoulder pain.

Table 2: History Findings and Associated Shoulder Disorders	
History	***Associated Conditions***
Age	*If younger than 40 years:* instability, rotator cuff tendinopathy, rotator cuff impingement and bursitis *If older than 40 years:* rotator cuff tear, adhesive capsulitis, glenohumeral arthritis
Diabetes or thyroid disorders	Adhesive capsulitis
History of trauma	*If younger than 40 years:* shoulder dislocation/subluxation *If older than 40 years:* rotator cuff tear
Loss of range of motion	Adhesive capsulitis, glenohumeral arthritis
Night pain	Rotator cuff disorders, adhesive capsulitis
+/- Neck pain, numbness, tingling, pain radiating past elbow	Cervical origin
Pain with overhead activity	Rotator cuff disorders, rotator cuff impingement and bursitis
Sports participation	Shoulder instability associated with overhead sports; impingement syndrome
Weakness	Rotator cuff disorders, glenohumeral arthritis

4. Key points for providers to consider:

- Shoulder pain is a common complaint seen in primary care.
- Subacromial impingement syndrome and rotator cuff disorder are the most common pathologies encountered.
- The history and physical exam are particularly important when used in combination for diagnosing shoulder dysfunction.
- Imaging studies are indicated for failed conservative therapy or an unclear diagnosis.
- Common reasons for inmates NOT to show improvement include failure to stop aggravating activities and failure to perform rehab exercises long enough (minimum of 8-12 weeks).

5. Effectiveness of Nonoperative Treatment:

Most patients with chronic shoulder pain can be initially treated nonoperatively with a combination of activity modification, physical or occupational therapy, medications, and corticosteroid injections, if necessary. This approach produces positive results in the majority of patients. **Referral to a specialist is indicated for patients with pain that is unresponsive to an appropriate regimen of nonoperative treatment.**

Activity modification is a simple yet effective approach for reducing shoulder pain.

- Reduction or avoidance of overhead activity or a painful arc of motion is the primary means for treating rotator cuff pathology, glenohumeral osteoarthritis, and adhesive capsulitis. The painful arc of motion occurs from 60 to 120 degrees at the shoulder.
- Avoiding heavy loading of the shoulder can reduce the pain associated with osteoarthritis.
- Bench pressing, triceps presses, dips, burpees, pull-ups, pushups, handball, and overhead throwing activities can exacerbate shoulder pain associated with impingement syndrome, osteoarthritis, and rotator cuff pathology (don’t forget to check with officers to see what the inmate may be doing on the compound).
- **Activities requiring sustained or repetitive reaching with the hands more than 8-10 inches from the body should also be limited as much as possible. This may require work restrictions for the inmate during treatment.**

Pain control is an important factor for the progression of treatment. The use of NSAIDs or acetaminophen can help in achieving this goal. The risks and benefits of each class of drug should be considered before use.

Physical or occupational therapy can include a large spectrum of treatments. There are therapeutic modalities that alleviate pain directly (heat and ice, ultrasound, iontophoresis), as well as stretching and strengthening exercises specifically designed to relieve pain while increasing overall shoulder function. If a patient has a poor response to the initial treatment for chronic shoulder pain, corticosteroid injections can be administered. **Patients may require a surgical referral if all conservative measures fail.**

The prognosis for chronic shoulder pain depends mainly on the underlying pathology, but the most common conditions respond favorably to conservative treatment overall. In general, the speed of recovery in chronic shoulder pain is slow and directly

related to patient compliance with activity modification and therapeutic exercise programs.

WARNING/CAUTION:

Many patients think that they should be better after they do their exercises for 3 weeks. Providers should emphasize to the inmates that they may need to do the exercises consistently for 8-12 weeks before they see even some improvement (maximal improvement may take 6 months or longer).

It can be enlightening to ask the inmate to demonstrate the exercises he or she has been doing. If the inmate is not able to immediately do the exercises without hesitation, then he/she is most likely not doing them often enough.

6. Clinical Pathway:

See attached algorithms for *Management of Chronic Shoulder Pain* and *Nonoperative Treatment Protocol for Chronic Shoulder Pain*.